

Innovative Attachment for Lingual Sheath for Unilateral Single Molar Crossbite Correction: A Case Report

Deepak Sindhu¹, Vinni Arora², Sachin Parashar³, Shakti Ghanghas⁴, Bhawya Chaudhary⁵, Vipul Jain⁶

^{1,4}, Junior Resident, department of Orthodontics, Postgraduate Institute of Dental Sciences, Rohtak

²Senior Resident, Maulana Azad Institute of Dental Sciences, Delhi

³Consultant Orthodontist, Ex Resident Department of Orthodontics and Dentofacial Orthopaedics, Post Graduate Institute of Dental Sciences, Rohtak

⁵ Junior Resident, Department of Periodontics, Manav Rachna Dental College, Faridabad

⁶ Dental officers, 356 Field Hospital, C/O 99 APO

ABSTRACT

This article describes a case report of unilateral single tooth crossbite treated with a new attachment which can be ligated with the lingual sheath welded onto the molar band which can be used to engage intra oral inter-arch elastics. The attachment is made of 20 gauge round stainless steel wire and is easy to fabricate.

INTRODUCTION

A crossbite is an aberrant occlusal relationship wherein a maxillary tooth is lingually positioned relative to its ideal position relative to an antagonist tooth (or teeth) or the mandibular tooth is facially positioned relative to its ideal position relative to an antagonist tooth (or teeth)¹. Based on location, it can either be anterior or posterior crossbite. This can also be classified on the basis of nature, of underlying cause, as skeletal, dental and functional crossbites. If the condition arises only from palatal malposition of a maxillary tooth with or without associated labial malposition of contacting mandibular teeth, it may be called as dental crossbite. Some etiologic factors responsible for single tooth crossbites are trauma to the primary incisors and displacement of the permanent tooth bud, delayed exfoliation of primary incisors and palatal eruption of the succedaneous tooth, supernumerary teeth, odontomas, ectopically erupting teeth can contribute to the development of dental crossbite.^{2,3} Sometimes in the finishing stages of class II correction cases, crossbite is experienced in molar region due to inadvertent use of intra oral elastics.⁴ This article presents the case with posterior unilateral crossbite of first molar which was managed with inter arch elastics.

CASE REPORT

An 18 year old male reported to orthodontic clinic with chief complaint of forwardly placed upper front teeth. He was diagnosed as Angle's class II division 2 malocclusion superimposed onto skeletal class II jaw bases. Patient was not willing for the orthognathic surgery, hence he was planned with non extraction orthodontic treatment in the first phase followed by a hybrid fixed functional appliance in the second phase. Once the molar relation was corrected to class I intra oral class II elastics were prescribed to the patient to maintain skeletal as well as dental class I relation. Patient went non-reporting after that due to his new job and he presented with unilateral single crossbite of 16 (figure 1 and 2).

Upper molar tubes had lingual sheaths (welded palatally on molar tubes) included from the beginning of the treatment for transpalatal arch ligated into them. Instead of removing sheath and welding lingual button on the band, a new attachment was designed which could be engaged in the lingual sheath for applying intra oral inter-arch elastics (figs 3-6). The attachment was bend with a 20 gauge S.S. wire and was ligated to lingual sheath in the same manner as a TPA in ligated. Patient was instructed for enter-arch elastic wear and was recalled every week. Correction was achieved in 3 weeks.

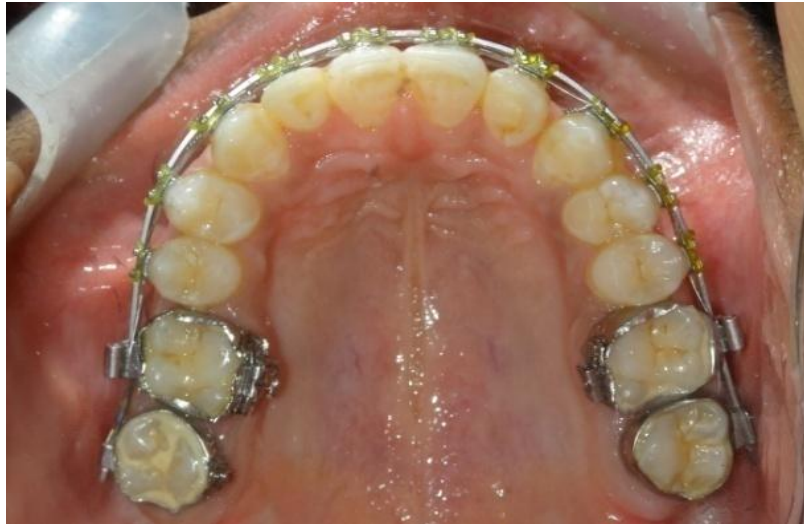

Fig.1 palatally displaced 16

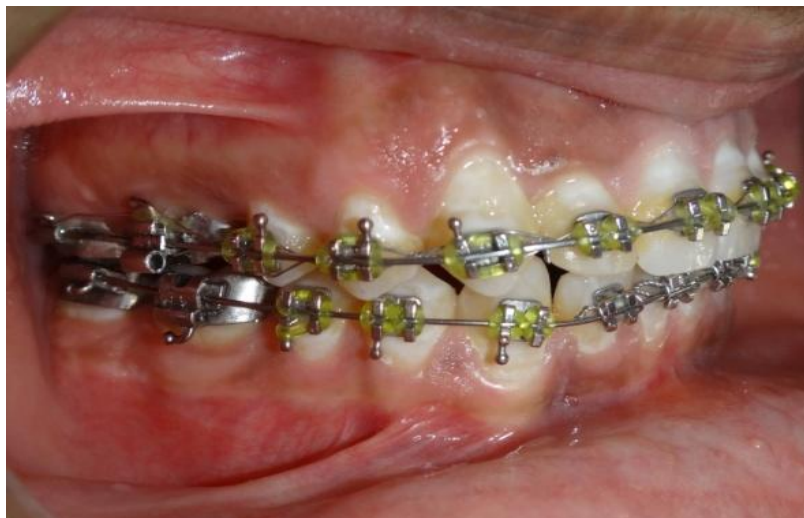

Fig. 2 molar in crossbite



Fig. 3: attachment design for lingual sheath

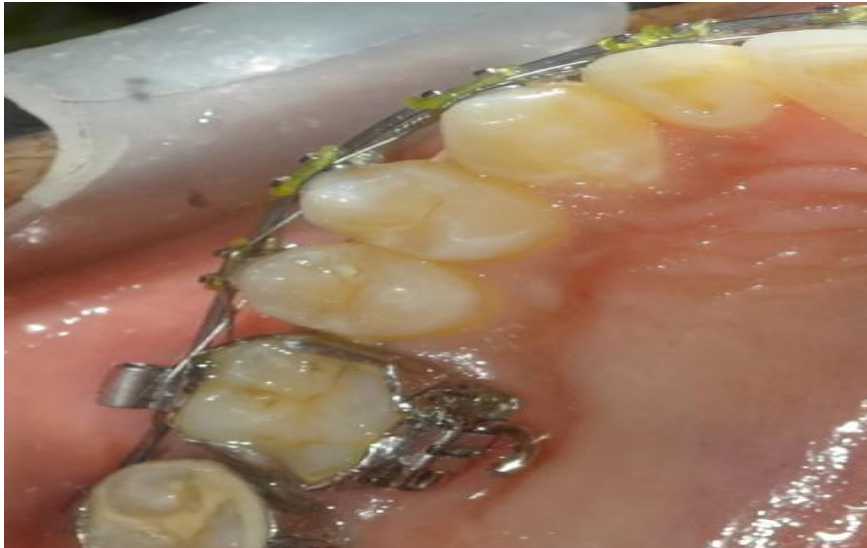


Fig. 4: Attachment ligated into lingual sheath

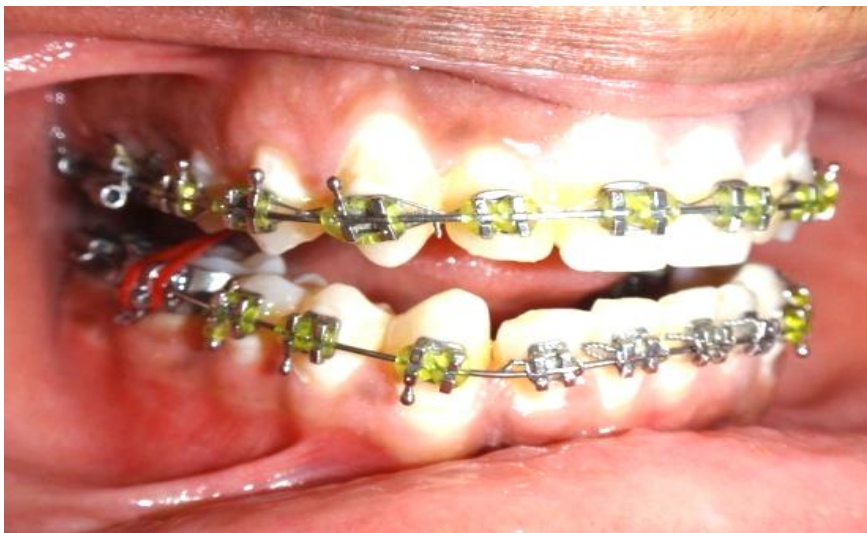

Fig. 5: Inter-arch elastic in place

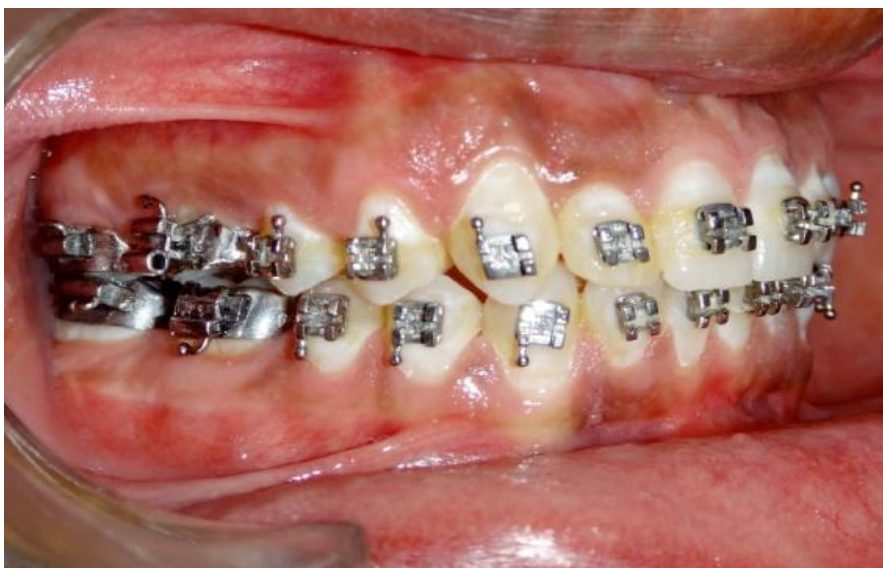

Fig 6: Final correction

DISCUSSION

Crossbites need to be intervened for correction as early as possible or else they can lead to serious oral health problems like a traumatic occlusion, which can result in attrition of teeth, mobility and apical migration of labial gingival leading to periodontal problems. A functional crossbite can result from any cuspal interference which results in mandibular shift which may lead to apparent mandibular asymmetry and temporomandibular joint dysfunction syndrome⁵. Several treatment modalities like the use of jack screws, molar palatal attachments (MPA), buttons with interarch elastics, slow expansion arches like W arch, omega loops, etc, rapid expansion appliances like Hyrax screws and Hass screws are available for treatment of single tooth or multiple teeth, anterior or posterior crossbites. Single molar crossbites when treated with inter-arch elastics, there is tendency of elastic to break due to occlusal interferences. By using the attachment we designed, elastics can be planned such that the elastic passes through the fossa of the molar. This attachment hook can also be constructed for more of horizontal effects and less of vertical effects by changing the length of hook going further palatally. Limitation of this method is that it is dependent on the patient compliance. Alternative method in such cases would be the use of expanded TPA or an expanded overlay wire in 1st molars' accessory slots.

CONCLUSION

The attachment described in the article can be a good alternate option of lingual buttons and can be explored for further applications when used with lingual sheath.

REFERENCES

- [1]. Schupak G E, Hung J, McNulty E C, Esthetics and orthodontics, Esthetic Dentistry (Third Edition), Mosby, 2015, Pages 318-337.
- [2]. Major P Glover K. Treatment of anterior crossbites in the early mixed dentition. J Canadian Dent Association 1992;58:574- 75
- [3]. Heilkinheimo K, Salmi k, Myllarneimi S. Long-term evaluation of orthodontic diagnosis at ages of 7 and 10 years. Eur J Orthod 1987;9:151-59
- [4]. *McLaughlin RP, Bennett JC, Trevisi H, Systematized orthodontic treatment mechanics , Mosby,2001*
- [5]. Joseph M Sim. Minor tooth movement in children 1977 (2nd ed) 272-301