

A Modified Risdon Approach to the Bilateral Subsigmoid Osteotomy; A Clinical Study

Running Title: Subsigmoid Osteotomy Approach

¹Bashar A. Tawfeeq – FICMS. MaxFacs

²Rawaa Younus Al-Rawee – MSc. MOMS.RCPSG.

³Bassam F. Yaseen - BDS. FICMS. MaxFacs

^{1,2,3}Department Of Oral And Maxillofacial Surgery, Al-Salam Teaching Hospital, Mosul, Iraq

ABSTRACT

Objectives: to improve accessibility to the surgical field and manipulation of Subsigmoid Osteotomy orthognathic surgery.

Materials and Methods: 32 patients operated for Bilateral Subsigmoid Osteotomy via extra-oral approach, the surgical tunnel stretched with a two Langenbeck retractors through 44 modified Risdon incisions.

Results: the time elapsed for an individual operation decreased in comparison with classical approach and with reduction of marginal mandibular nerve damage.

Discussion: the outcome related to duration of operation and satisfaction of the operator is improved clinically following the use modified Risdon extra-oral approach through the soft tissue tunnel.

Keywords: Langenbeck Retractor, Modification, Orthognathic Surgery, Risdon Incision.

INTRODUCTION

Risdon approach is a surgical technique to approach the mandible, first described by F. Risdon in 1934, in which the mandible is approached extra-orally through an incision below and behind the angle of the mandible⁽¹⁾. This low height approach being below the marginal mandibular nerve, is the most crucial point in the Risdon approach⁽²⁾, which could be retracted easily without much dissection, and if a flap is elevated, including the nerve, there is no risk of facial nerve damage⁽³⁾. This approach is easily learned and performed, and allows less exposure of the mandibular ramus and condyle, and most surgeons would agree that this approach insufficiently exposes condylar fractures⁽⁴⁾.

Minimal risk of neurosensory disturbance and Temporo-mandibular joint (TMJ) disturbance were reported as the benefits of extra-oral bilateral vertical subsigmoid osteotomy (BVSO) operation⁽⁵⁾, while poor visibility and the need for inter-maxillary fixation for several weeks has been its main drawbacks⁽⁶⁾. The higher incision provided better access, as far as esthetic qualities were concerned the two incisions fared equally well. We recommend the use of the lower incision 3cm below the lower border of mandible as it definitely reduces the chance of postoperative lower labial palsy⁽⁷⁾. Objectives: to improve accessibility to the surgical field and manipulation of subsigmoid osteotomy orthognathic surgery.

PATIENTS AND METHODS

Thirty-two patients operated as bilateral vertical subsigmoid osteotomy (BVSO) via extra-oral approach, from (2004-2014), in oral and maxillofacial department in Al-Salam teaching hospital in Mosul city. The extra-oral surgical approach is limited to the Risdon incision – 64 incisions (below and behind the angle of the mandible), ten patients were operated with classical Risdon approach (20 Risdon incisions) while 22 patients (44 Risdon incisions) operated with new modified approach. The surgical fields bluntly tunneled with periosteal elevators and dissecting the underlying periosteal cover to engage the angled blades of the two medium size (13x45mm) Langenbeck retractors underneath the periosteal margins of

the soft tissue tunnel, then make a trial to stretch the bulky tissue between the skin and periosteum with Langenbeck retractors. The two retractors pulled with controlled force in a trial to stretch the operative field in two directions, each direction perpendicular to the other. The osteotomy performed with a conventional straight surgical handpiece; without intra-osseous but inter-maxillary fixation (IMF) for 1.5 month duration. Time of operation and complexity of the manipulation, both are assessed to evaluate the outcome of the approach modification.

RESULTS

The newly created window moves freely with three cat's bow retractors up and down with minimal muscular tension of Masseter muscle, Figure (1).

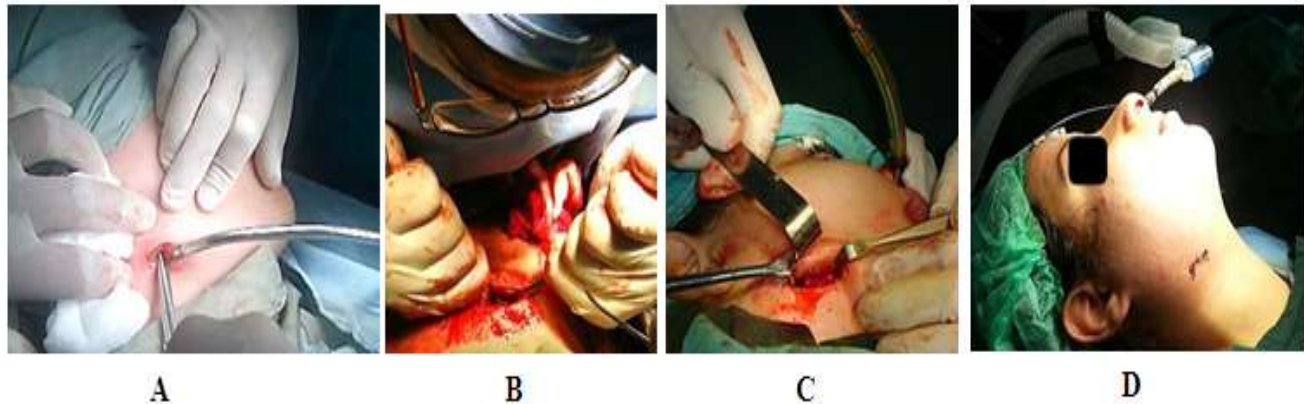


Figure 1: A. classical Risdon incision, B. and C. modified approach by stretching the tunnel in 2 directions, D. post-surgical wound closure.

The average time of aBVSO operations in classical Risdon approach is 115 min (including osteotomy with IMF, without intra-osseous fixation), but the average operative time when using the modified approach reduced to 70 min. The whole patients who operated with classical and modified approach do not have a weakness in the lower lip motor function. Regarding the surgical staff, the new modified approach facilitates the osteotomy procedure to unlimited level. Two incisions (4.5%) out of 44 modified Risdon incisions were complicated by slippage of the retractor inducing tear which confined only to skin, the resultant fault corrected with fine suturing without unwanted scar complication. The patients followed for expected healing's complications, the outcome of masticatory function following inter-maxillary fixation resemble that of classic Risdon approach without negative clinical finding, indicate normal healing process of the masseter muscle.

DISCUSSION

The osteotomy procedure being easier than classical approach in spite of the same incision length in the modified approach, but it provides a lax window, which could be moved freely in all directions, facilitating surgical manipulation to achieve osteotomy. In addition, retraction during the operation does not intensify assistants throughout the operation and provide simple effort to explore the surgical field.

Weak motor function, neuropraxia (if occur) could be due to excessive tissue manipulation following powerful stretching of soft tissue, so this approach do not carry a risk of neurotmesis. The time elapsed in an individual operation for an arch bar is about 20-25 min, while that for bilateral Risdon incision and blunt dissection is 4-6 min., the remaining time 39-46 min distributed among the osteotomy procedure bilaterally in modified Risdon approach, while that time in classical Risdon approach for the bilateral osteotomy were 84-91 min.

A study provided by Rajarshiet al in 2013, they conclude that the high incision group had a significant occurrence of lower labial palsy i.e. 7 out of 10 cases. The average duration of palsy was 12 weeks. In the lower incision group the occurrence of palsy was significantly low, only 1 out of 10 cases and it lasted for 1 week.

Other study by Ganeval et al who use a twenty Risdon incision, they conclude that in all cases, the planned surgery could be performed using this approach. The only complication was a case of temporary paresis of the facial nerve's mandibular branch. The scar was always considered as quite acceptable⁽⁸⁾.

The two incisions out of 44 modified incisions which complicated with skin tear end with normal clinical healing process, due to superficial wounded defect that confined only to skin but not the underlying layers. The operative outcome related to duration of operation and satisfaction of the surgical staff are improved clinically following the use modified Risdon approach through the soft tissue tunnel, this outcome coupled with low neural and operative morbidity. The main advantages of this modified approach are improved accessibility and ease manipulation.

CONCLUSION

It may be concluded that this modified Risdon approach is a good surgical approach to the mandible on the basis of clinical results.

REFERENCES

- [1]. Risdon approach, Edited by Robert Ireland in A Dictionary of Dentistry, Published in print January 2010 | ISBN: 9780199533015, Published online January 2010 | e-ISBN: 9780191726606.
- [2]. Bhavsar D, Barkdull G, Berger J, Tenenhaus M. A novel surgical approach to subcondylar fractures of mandible. J Craniofac Surg. 2008;13:496–499. doi: 10.1097/SCS.0b013e3181539b8b. [PubMed] [Cross Ref]
- [3]. Lutz JC, Clavert P, Wolfram-gabel R, Wilk A, Kahn JL. Is the high submandibular transmasseteric approach to the mandibular condyle safe for the inferior buccal branch? SurgRadiol Anat. 2010;13:963–969. doi: 10.1007/s00276-010-0663-z. [PubMed] [Cross Ref]
- [4]. Kanno T, Mitsugi M, Sukegawa S, Fujioka M, Furuki Y. Submandibular approach through the submandibular gland fascia for treating mandibular fractures without identifying the facial nerve. J Trauma. 2010;13:641–643. doi: 10.1097/TA.0b013e31819ea15f. [PubMed] [Cross Ref]
- [5]. Seung Min Nam, Jang Hyun Lee, and Jun Hyuk Kim, The application of Risdon approach for mandibular condyle fractures, BMC Surg. 2013; 13: 25.
- [6]. Charles P. Sia, DMD, PDipDS, Internal versus intermaxillary fixation in vertical subsigmoid osteotomy for mandibular setback: a randomized controlled trial, September 2011
- [7]. Rajarshi Bandyopadhyay, Subhrangsu Basu, Mayukh Misra, Submandibular Surgical Approach – A Clinical Evaluation, RUJODS, Ranchi University, Vol - 2 No.-1 June 2013.
- [8]. A Ganeval, S Zink, D Del Pin, J-C Lutz, A Wilk, P Barrière, Modified Risdon approach for non-traumatic ramus surgery, Revue de stomatologie et de chirurgie maxillo-faciale. 2012; 113(2):96-9.