

Biomechanical, Histomorphometric & Histomorphological Evaluation of Miniscrew with Topical application of Ozonated Olive Oil in Experimental Control Diabetic Sample (Dog)

Running title: Ozonated Olive Oil, orthodontic miniscrew

Hussain Al-Obaidi (B.D.S, M,Sc)¹, Zaid Burhan Al-Dewachi (B.D.S, M,Sc)²

¹Full Professor in Department of Orthodontic, Paedodontic, and Preventive Dentistry, Mosul University, Iraq

²Lecturer in Department of Orthodontic, Paedodontic, and Preventive Dentistry, Mosul University, Iraq

ABSTRACT

The primary aim of the study research is to evaluate the stability of orthodontic (MIs) after treated with Ozonated Olive Oil (Local Application), and assess Histomorphometric & Histomorphological of the bone Surrounded the Orthodontic (MIs) in Control diabetic sample (Dog).

Material & Method: twelve male beagle dogs weighting (15-20 kg) with average of (16.71kg) and aged between (1.5-2 year) were divided into two groups, Alloxan solution was given intravenously at a dose of 60mg/kg as a single dose. This dose was chosen because it was effective in inducing diabetes. The control of Diabetes is done by giving oral anti-diabetic metformin 1700mg/dog /day with average of (101.73mg/kg) alone or in combination with oflente insulin (0.25U /kg- 0.7 U/kg) twice daily. , the insertion of (MIs) proceed by local application of is 6.65μL that represent also the volume of the Ozonated Olive Oil that is pushed in each (MIs) holes

Results: the primary stability is more in control group than experimental group, the secondary stability is more in experimental group than control group, there is a significance differences in secondary stability between the control and experimental group at significance level $p < 0.05$. Histomorphometric & Histomorphological assessment reveal that No significance differences in cortical bone thickness (CBT)%, Osteoblast count between the control and the experimental Group, with highly significance differences in (CBIC%), (CBA%), and Osteoclast count between the control and experimental group at significance level $p < 0.05$.

Conclusion: the Ozonated Olive Oil Play a role in secondary stability of miniscrew (MIs), there is a great effect on cortical bone implant contact (CBIC), with increase cortical bone area (CBA) , with no effect on cortical bone thickness (CBT) and osteoblast count .

Key Words: Orthodontic miniscrew (MIs), Periotest value (PTV), cortical bone thickness (CBT), cortical bone implant contact (CBIC), cortical bone area (CBA).

INTRODUCTION

The use of the (MIs) for orthodontic anchorage has shown better results in orthodontic treatment⁽¹⁾, Diabetes mellitus is a group of metabolic diseases in which a person has high blood sugar, either insulin dependent or non-insulin dependent. 2, Now a day, more diabetic patients are seeking orthodontic treatment than before beside that Diabetes mellitus has long been considered a relative contraindication to dental implant therapy and is increasingly becoming one of the most commonly faced contraindications to dental implant therapy⁽²⁾, glycemic control has long been the primary consideration for implant patients with diabetes, this appears appropriate given the correlations between glycemic control and microvascular and macrovascular complications⁽³⁾. It is important to know the effects of diabetes, glycemic control on bone metabolism and bone implant integration and must be considered these effects for implant therapy, the majority of the studies identified in this field were undertaken with the fundamental view that good glycemic control is critical to the successful use of implant therapy for patients with diabetes⁽⁴⁾. The Ozone (O₃) can be administered topically or locally as a gas or as ozonated water, Olive Oil or sunflower oil and because its disinfectant

properties and has been used in treating early carious lesions, in sterilization of restoration cavities before filling, in root canals and in the treatment of periodontal pockets as well enhance as to epithelial wound healing in ulcerations and herpetic lesions beside that O₃ therapy was found to be beneficial in the treatment of refractory osteomyelitis in combination with antibiotic treatment, surgical interventions and hyperbaric oxygen, Complete healing of osteonecrosis of the jaw (ONJ), following bisphosphonate treatment, was achieved after a few applications of O₃ in combination with antibiotic therapy⁽⁵⁾, Ozone had pan-bactericidal, pan-viricidal, antifungal and antiprotozoal therapeutic effect, In addition, it improves oxygen supply in tissues so leading to rapid healing process Ozonized oil had been used locally for disinfecting lesions and promoting their healing, beside that Ozone gas reacts with the carbon double bonds in plant oils and this leads to the formation of ozonoids, and the effects of these agents on infection control and wound management⁽⁶⁾.

The mixing of ozone With Olive oil was reacted to produce thick viscous Ozonated Oil, and this reaction When happened, will lead to the direct reaction of O₃ with unsaturated fatty acid present in bacterial cytoplasmic membranes, these oxidation products are at least partially responsible for the microbicidal activity of this oxidant and enhanced polarity, which in turn increase the capacity to cause the disruption of such membranes⁽⁷⁾. Ozone is highly energetic activated form of oxygen, which has been used in management of gingivitis and periodontitis with no reliable data obtained regarding the direct effect of ozone⁽⁸⁾. Independently of blood glucose levels, aqueous ozone irrigation of Wistar rats' standard femoral wounds improved capillary neo formation and enhanced osteoclast migration in wound healing regions without interference in bone trabeculae neo formation⁽⁹⁾.

MATERIAL AND METHOD

A. EXPERIMENTAL ANIMALS

Twelve male beagle dogs weighting (15-20 kg) with average of (16.71kg) and aged between (1.5-2 year) were obtained from the animal house of college of Veterinary Medicine, Mosul University have been divided into two groups (6 dogs in each group, first group is the control group that represent the control diabetic without any medical treatment of miniscrew, other group that represent the miniscrew with topical application of Ozonated Olive Oil), All dogs Appeared clinically healthy, with normal periodontal appearance as determined by physical and clinical mouth examination, Normal haemogram and clinical chemical profiles, the dogs were housed Separately in a controlled environment each of them in single metalcage and fed a home-made diet containing chicken and rice twice a day with sufficient tap of water all the period of study, the animal selection, management and surgery protocol were approved by the animal care center in the college of veterinary medicine of Mosul University, the experimental segment of the study started after an adaptation period of 2 months.

B. INDUCTION AND CONTROL OF DIABETES

The Dogs were fasted for 24 h prior to the induction, the Blood was collected for determination of biochemistry profile including serum alanine transaminase (ALT), Alkaline phosphatase (ALP), Triglyceride (TG), cholesterol, electrolytes, Catheters were placed in the cephalic vein, Fresh solution of alloxan monohydrate (Sigma, USA) for diabetes mellitus induction was primed just prior to injection⁽¹⁰⁾. Alloxan solution was made by dissolving it in normal saline at a concentration of (100 mg/ml), this prepared solution was given intravenously at a dose of 60mg/kg as a single dose. The control of Diabetes is done in Some diabetic dogs by giving oral anti-diabetic metformin 1700mg/dog /day with average of (101.73mg/kg) that have been divided into two equal parts (two tablets of 500mg at the morning and one tablet & half of 500mg at the evening that given with the meal, But in other cases the metformin will not adjusting enough to control the diabetes induced by alloxan, that need to use a combination of metformin 1700mg with use of lente insulin (Mixture of 30% semi-lente and 70% ultralente insulin) (0.25U /kg- 0.7 U/kg) twice daily.

C. SURGICAL PROCEDURE

The dogs must be fastened overnight before anesthesia, but access to water continues till the anesthesia given, each group was treated in Separated days in the morning, before (MIs) placement, all animals were sedated with ketamine 10% (2.2 mg/kg intramuscularly) and Xylazine 2% (0.22 mg/kg intramuscularly), this dose of sedation keep the dog anesthetized for one hour, Before doing the implant insertion, we applied the 0.2% Chlorhexidine gluconate as disinfectant to the implant area by the gauge, then determined the exact location of implant insertion using Well sterile wood landmarks that measured the distance from the cusp tip of second, third, and fourth premolars downward till 18mm, and the first molars till 20mm in the Mandibule, were placed in the furcation and between the teeth, depending on space availability in each dog. All the inserted (MIs) of (Dentos Company, Korea, 1.3mm diameter and 7mm length) was done in the non-keratinized gingiva. After punching of the non-keratinized Gingiva, the drilling of the bone is done by using 1.1 mm drilling bur, with Surgical hand piece connected to implant Surgical engine at 1600(rpm) speed with 35 newton /cm torque, clockwise rotation with profuse sterile normal saline solution at room temperature (25°C) was used to irrigate the site and maintained continuously throughout the drilling by sterile disposable syringe. The

determination of Ozonated Olive Oil (Aurora ,oxy, USA) volume that is used in experimental Group depend mainly on the size of the bone room that equipped by (MIs), that in turn depend on the diameter and the shape of the bur used for drilling, the height of drilling that determined adequate room to fill with Ozonated Olive Oil and (MIs). The diameter of bur is round ,the shape is cylinder ,the diameter is 1.1mm,the height of drilled bone that accommodate to engage the (MIs) is 7mm,so the volume of (MIs)room is calculated by multiplying $(0.55 \times 0.55 \times 3.14 \times 7)$ the result is $6.65 \mu\text{L}$ that represent also the volume of the Ozonated Olive Oil that is putted in each (MIs)holes before insertion of (MIs) this is need the use of micropipette graduated from $(5-200 \mu\text{L})$.After complete the (MIs) rooms' preparation and dropping of Ozonated Olive Oil in its actual sites prepared, then we start (MIs) insertion according to standards Protocol, that using hand driver (MIs) with the 90° perpendicular to the cortical bone and paralleling to the occlusal plane .(Fig.1)

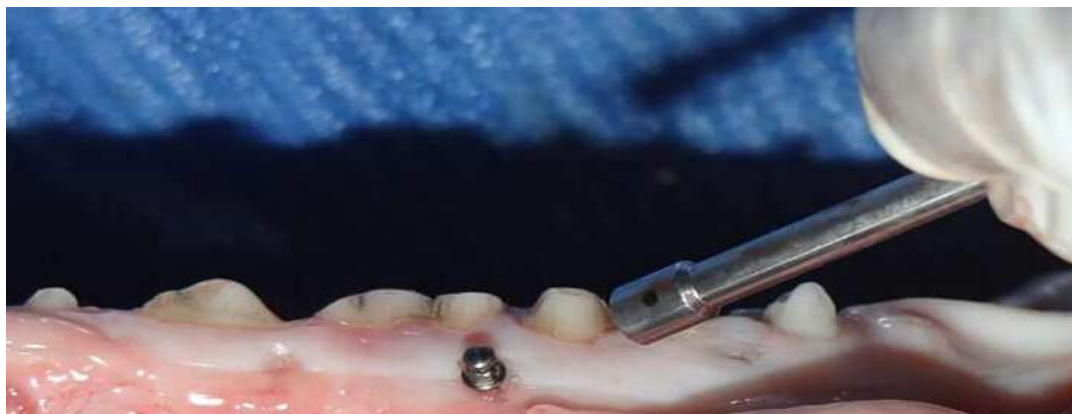

Figure (1) (MIs) in its ideal Position 90° to the cortical bone with Paralleling to the occlusal plane

D. IMPLANT STABILITY TESTS

The implant stability test was done for each implant at the beginning and at the end of fourth week.

E. UNSCREWING OF(MIS)&FIXATION FOR HISTOLOGY

At the completion of the 12-week experimental period, the dogs were euthanized, and the mandibles were disarticulated, at necropsy, the mandible were re-claimed by sharp dissection, the soft tissue was removed by surgical blades, each bone-implant sample was reclaimed with a modified 10-mm-diameter bur with the use of abundant irrigation. The samples were cut parallel to the long axis of the implant to reduce scatter during scanning,, then the two halves of the mandible fixed for two weeks at room temperature, in 10% neutralized buffered formalin prepared by mixing 100ml strong formalin and 900ml tap water to receive 10% formalin, then sodium dihydrogen Phosphate, monohydrate / $\text{NaH}_2\text{PO}_4 \cdot \text{H}_2\text{O}$ 4gm and disodium hydrogen phosphate ,anhydrous / Na_2HPO_4 6.5gm,were added to change the one liter of 10% formalin to one liter of 10% neutral buffered formalin, The Specimen consists of (MIs) and the surrounding bone that were excised using Diamond disc from the whole mandible, then the specimens after cut ,put it in the formalin.

The specimens removed from formalin for (MIs) unscrewing, this procedure had be done using Implant Surgical engine with screw holder attached to the engine hand piece, with very low speed at 20 rpm counter clockwise direction, this procedure done before decalcification of the bone in order to prevent deterioration of the bone sample details if this procedure done after decalcification⁽¹¹⁾. Then after that the bone specimen returns back to formalin for two weeks fixation, the bone sample transfer from buffered formalin into the decalcifying solution (which is a mixture of 8% formic acid and 8% hydrochloric acid), the duration of this step procedure is 7-14 days. After the decalcification had been finished, the next step include several times washing to remove the acid remnant ,then the bone tissue gradually move to pure alcohol(70° ethanol; 80° ethanol; 95° ethanol; absolute ethanol 100°) for dehydration procedure ,then followed by clearing procedure by holding it in Xylene Solution. The Section thickness taken from the block tissue is (4μ) by rotary microtone, the cut done vertically parallel to the long axis of the implant (longitudinal section), the cut done in the middle of the implant site taking imaginary line pass through the middle of long axis of (MIs), and because the (MIs) diameter is 1.3mm which is equal to 1300micron, and the section thickness is (4μ) , so by diving $1300/4$, the result 325sections can be obtained, then the Cutted section putted on the slide and painted with Hematoxylin and Eosin stain, and examine under light microscope.

F. HISTOLOGICAL EVALUATION

The Histological assessment done with the aid of Image J2x Software Program (Image J2x 2.1.4.7, image 2, Rawak software Inc.), the assessment include the measurement **Cortical Bone Implant Contact (CBIC)**This was be done by measuring the whole bone length continuity that's come in contact with the implant on both side of the implant (tension

&pressure side) and then divided by the length of the implant multiplying by 100, this measurement should be done on three sections and divided by three and take the average that represent the final result, **Cortical Bone Thickness (CBT)**, This measure represent the thickness of cortical bone adjacent to the implant from the outer margin to the inner margin of cortical bone that representing the linear distance which parallel to the long axis of the implant from the lowest point of the inner margin to the highest point of the outer margin of cortical bone adjacent to implant, **Cortical Bone Area (CBA)** This Percentage measurement can be obtained by dividing the surface area within the thread over the surface area of the whole thread, the result multiplied by 100, this measurement intended to be done on four threads, then the average taken as result ⁽¹²⁾, and lastly the **Counting of the number of Osteoblasts & Osteoclast**.

RESULTS

In the insertion stage, primary stability, the mean values of Periotest stability measurement were -2.48 ± 0.10 in Control group, and -3.18 ± 0.16 in Ozonated Olive Oil group as a result of insertion, all the micro implant begin again checked for secondary stability after one month, the secondary stability decreased to a mean of -1.37 ± 0.077 for the Control group and increased to 3.64 ± 0.15 for Ozonated Olive Oil group, (Fig.2) Simplified the primary stability differences between the entire study groups and (Fig.3) Simplified secondary stability differences between all of the study groups.

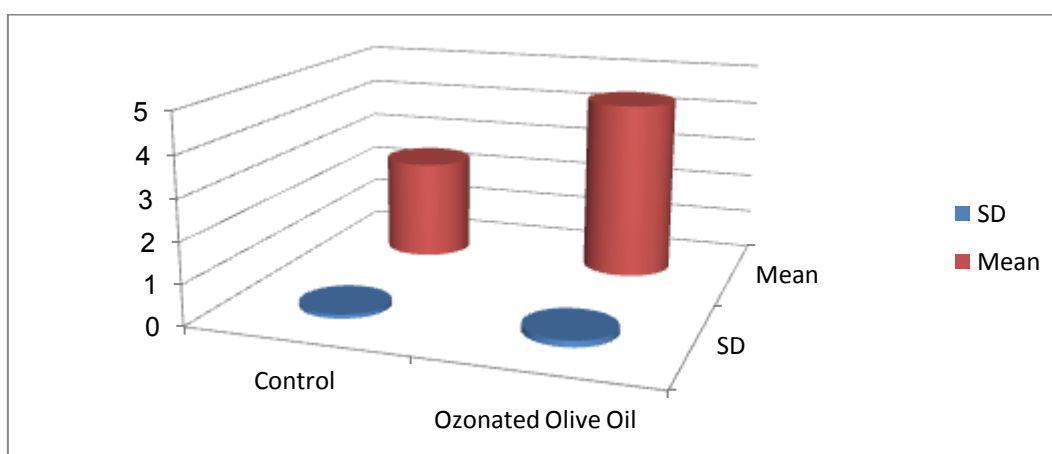


Figure (2) represents the descriptive statistics of Primary Stability PTV for all Groups

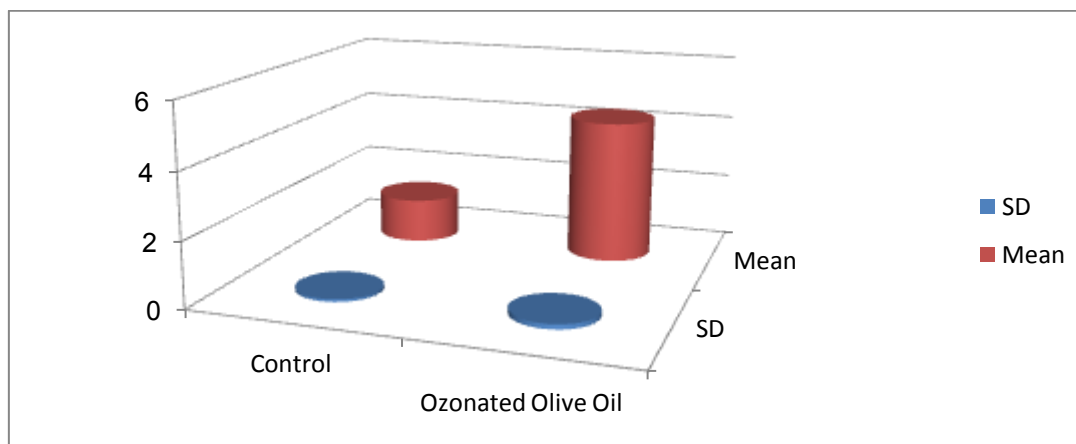


Figure (3) represents the descriptive statistics of Secondary Stability PTV for all Groups

For the statistical test, the results of comparing the primary and secondary for each group using t-test and significance at $p < 0.05$, showed a significant increase in the stability value after four weeks healing period as represented by secondary stability in the Ozonated Olive Oil while significant decrease in stability value as represented by secondary stability for control group table(1)

Table (1) the comparison between the primary and secondary stability of all the groups

Study Groups	Stability Comparison	Primary stability		Secondary stability		t-value	p-value
		Mean	S.D	Mean	S.D		

Control	Primary vsSecondary	2.48	0.109	1.37	0.077	64.527	<0.001*
OzonatedOlive Oil	Primary vsSecondary	3.18	0.162	3.64	0.156	-17.03	<0.001*

*Significance at $p < 0.05$, all measurements in Periotest.

While on comparing the Secondary stability between Control group and the Ozonated Olive Oil group, there is a significant changes observed in the comparison between them at significant level $p < 0.05$ as shown in table (2).

Table (2) the comparison of Secondary Stability between the control group and Ozonated Olive Oil

Groups	Mean \pm S.D	t-value	p-value
Control	1.37 \pm 0.077	-101.694	<0.001*
OzonatedOlive Oil	3.64 \pm 0.156		

*Significance at $p < 0.05$, all measurements in Periotest

The descriptive Histological Evaluation was shown that the examination was done with light microscope at 4x, 10x, and 40x magnifications, the the experimental group shows evidence of new bone formation in all bone areas adjacent to the implant threads beside that there is highly bone formation (new bone formation) and maturation that migrate to the areas between the implant threads when comparing with the control group, that mean the level of bone formation and maturation in control group is less than that of the experimental group, the level and the evidence of bone formation of higher and more apparent in the Ozonated Olive Oil group, in this experimental group there is a close contact between the implant surface and the newly formed mature bone with a cellular osteoid tissue showing fibrous connective tissue and blood vessels perceived ,also the Histological picture revealed that there is a large number of osteoblast present in the areas adjacent to the implant threads that reflect also the highly rate of mature bone formation in this group, the Bone surfaces facing the implants shown cellular proliferation and differentiation, stimulating The organized type of mature bone, or lamellar bone tissue, beside that there is a formation of the primary osteons with a picture of immature bone tissue, was noted.

HISTOMORPHOMETRIC EVALUATION

CORTICAL BONE THICKNESS (CBT):

The cortical bone thickness measurements of the study groups using the Image J2x Software in pixels, showed a mean value \pm standard deviation of 737.2 \pm 4.91 for the control group, 739.05 \pm 4.16 for the ozonated olive oil group (Fig.4) on observation of the histogram, the highest mean value was noticed for the Ozonated Olive Oil and the lowest mean value was noticed for the control group, for the statistical test ,the result of comparing cortical bone thickness mean value between the Control and the experimental study group using paired t-test and significance at $p < 0.05$, showed a non-significant between the control and the Ozonated Olive Oil groups as shown in(table 3).

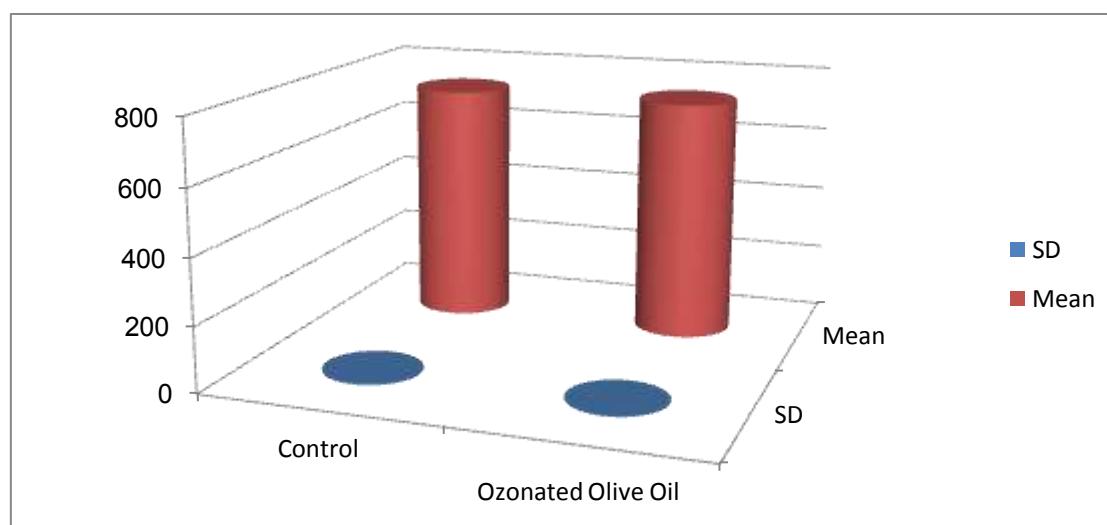


Figure (4) shows the descriptive statistics of cortical bone thickness values for all groups

Table (3) the cortical bone thickness comparison between the control and the experimental group.

Groups Comparison	Control Group		Experimental Groups		t-value	p-value
	Mean	SD	Mean	SD		
Control vsOzonated Olive Oil	737.2	4.91	739.05	4.16	-1.92	0.06

All measurements are in pixels.

CORTICAL BONE IMPLANT CONTACT % (CBIC)

The cortical bone implant contact % of the study groups using the Image J2x software shows the following values of 52.82 ± 4.82 for the control Group, 64.72 ± 2.96 for the Ozonated Olive Oil group (Fig.5), on reflection of histogram the highest mean value for the Experimental group and the lowest mean value for the control group, When comparing the means between the control group and the experimental group using paired t-test, there is a highly significance differences between the control and the experimental group at significance level $p < 0.05$ as shown in the table (4)

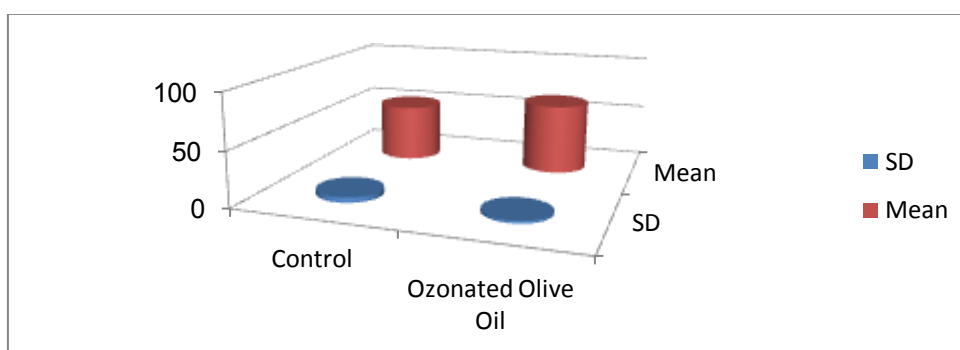


Figure (5) shows the descriptive statistics of Cortical Bone Implant Contact % (CBIC) of all the groups

Table (4) shows the cortical bone implant contact % (CBIC) comparison between the control and the experimental group

Groups Comparison	Control Groups		Experimental Groups		t-value	p-value
	Mean	SD	Mean	SD		
Cont. vsOz.OliveOli	52.82	4.82	64.72	2.96	-13.76	<0.001*

* Significant at $p < 0.05$, all measurements are in Percentage.

CORTICAL BONE AREA % (CBA)

The cortical bone area % of the study groups using the Image J2x software shows the following values of 67.32 ± 6.66 for the control group, 74.12 ± 5.89 for the Ozonated Olive Oil group (Fig.6), on reflection of histogram the highest mean value for the Ozonated Olive Oil and the lowest mean value for the control group, When comparing the means between the control group and the experimental group, using paired t-test, There is a highly significance differences between the control and the experimental group at significance level $p < 0.05$ as shown in the table (5)

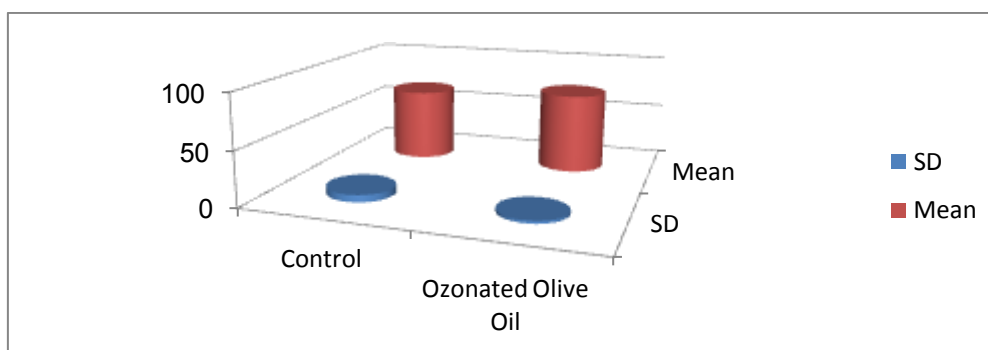


Figure (6) shows the descriptive statistics of Cortical Bone Area Contact % (CBA) of all the groups

Table (5) shows the cortical bone area% (CBA) comparison between the control and experimental group

Comparison Groups	Control Group		Experimental Groups		t-value	p-value
	Mean	SD	Mean	SD		
Cont. vsOzon.Oli.Oil	67.32	6.66	74.12	5.89	-5.62	<0.001*

* Significant at $p < 0.05$, all measurements are in percentage

FIBROBLAST COUNT

The counting of Osteoblast cells done by the naked eye using the light microscope, the counting done through the four thread of each section, and then taking the average counting of three sections, the descriptive statistics of fibroblast counting shows the average \pm standard deviation for the control group of 100.62 ± 8.9 , for the Ozonated Olive oil Group 98.37 ± 4.2 , while when comparing between the groups using paired t-test, shows no significance differences between the control and the Ozonated olive oil group, with highly mean counting value for the control group at significances level $p < 0.05$ table(6).

Table (6) shows the Fibroblast cell count comparison between the control and the experimental groups

Groups Comparison	Control Groups		Experimental Groups		t-value	p-value
	Mean	SD	Mean	SD		
Control vsOzonated Olive Oil	100.62	8.9	98.37	4.24	1.49	0.15

All measurements are in number.

OSTEOCLAST COUNT

The counting of Osteoclast cells done by the naked eye using the light microscope, the counting done through the four thread of each section, and then taking the average counting of three sections, the descriptive statistics of Osteoclast counting shows the average \pm standard deviation for the control group of 8.7 ± 2.6 , for the Ozonated Olive oil Group 5.3 ± 1.44 , in Comparison between the groups using paired t test, the result show significance differences between them at the significance differences $p < 0.05$ (table 7).

Table (7) shows the comparison of osteoclasts number between the control and the experimental group

Groups Comparison	Control Group		Experimental Groups		t-value	p-value
	Mean	SD	Mean	SD		
Cont. vs Ozonated Olive Oil	8.7	2.6	5.3	1.44	6.40	<0.001*

* Significant at $p < 0.05$, all measurements are in number.

DISCUSSION

The Initial stability of implants can be significantly less in bones of low density or insufficient volume, also larger bone-to-implant contact fractions have been reported in bone sites of higher density, beside that The length of the dental implant, its diameter, its design, as well as the micro-morphology and the type of implant surface are considered key factors inducing primary stability⁽¹³⁾. Sufficient primary stability prevents micro-motions between the surface of the implant and the surrounding bone also the Secondary stability, which is associated with healing and increases in total MSI stability, first becomes apparent three weeks after miniscrew placement and can be tested at the beginning of fourth weeks⁽¹⁴⁾. In regarding the comparison between primary and secondary stability, in the present study results showed a significant higher PTV of secondary over primary stability in ozonated olive oil group, but higher primary over secondary stability in control group, further the statistical comparison of secondary stability between the control and experimental study group showed a significant higher PTV of secondary stability in experimental group over control group. The present study results agreed with Mahesh et al.,(2014)⁽¹⁵⁾, who study the local effect of implant hole grafting with calcium phosphor –silicon putty on secondary stability that increased over the primary stability if compared with control group (non- grafted).

The current study explain that, the primary bone that formed after the implant insertion is weak bone not fulfill the complete integration of bone with implant, and that weak bone had replaced after the 4th week or between the 5th and 6th

by more strong lamellar bone and this explain why the secondary stability in experimental group is larger than primary stability when comparing with control group and this agree with the study conducted by Turner & Nentwing, (2014)⁽¹⁶⁾. The Histomorphological Evaluation reveals that, The bony reaction to (MIs) insertion include the formation of secondary bone (osteon), the bony reaction to the rough surfaces of implant (machine surfaces) characterized by formation of spongy bone that later undergoes the calcification and transform to calcified bone, another type of bone that form adjacent to the smooth surface of the (MIs) and called distance osteogenesis⁽¹⁷⁾, There is a picture of trabecular bone formation with abundant of osteoblast and some or few numbers of osteoclast scattered in the areas adjacent to threaded (MIs) which is more prominent in ozonated olive oil group in comparison with the control group. On the other side the picture of woven bone is more and prominent than the secondary trabecular bone in the control than the experimental group and these results agreed with the result obtained by (Cardemilet al., 2015)⁽¹⁸⁾. The results of histomorphometric analysis showed significance higher values for cortical bone thickness for experimental group over the control group.

For the CBIT% and CBA% both shows higher values for the Ozonated Olive oil group over the control group, for the osteoblast count a significantly higher osteoblast count of the control over the experimental with non-significance between the control and the Ozonated Olive Oil groups, for the osteocytes count a significantly higher count in the experimental over the control group with the non-significance between the control and the Ozonated Olive Oil groups, Lastly for the osteoclast count shows simply the highly average value for the control group and the lowest mean value for the experimental group with a significance differences between the control and the experimental. The short-term administration of cyclosporine in conjunction with topically applied Ozonated oil may exert a significant influence on bone density, beside that the Ozone therapy appears to act as a biological response modifier Increased bone remodeling and trabecular bone loss have been observed in cyclosporine exposed animals with increased osteoblastic and decreased osteoclastic (El Hadaryet al., 2011)⁽¹⁹⁾. and this agree with the current study research., The present research results partially agreed with Erdemciet al., (2014)⁽²⁰⁾, who's stated that after preparation of histological sections all the mineralized, trabecular bone, osteoid and osteoblast surfaces were measured. Measurements of the trabecular bone showed statistically higher values in the groups treated with systemic ozone than in the groups that underwent topical ozone administration and concluded that postoperative long-term systemic ozone application can accelerate alveolar bone healing following extraction in rat.

Niedźwiedzki & Filipowska (2015)⁽²¹⁾ stated that the course of bone remodeling at the cellular level is mainly associated with the activity of osteoclasts and osteoblasts, recently also osteocytes have gained a growing interest as the principal regulators of bone turnover. Osteocytes play a significant role in the regulation of osteogenesis, this probably could explain their combined presence in the present research, during the bone formation and maturation in all groups., Bone-to-implant contact, usually reported as a percentage of the total implant surface area, is the common way that implants are evaluated histologically; an increase in the percentage of bone-to implant contact indicates a corresponding increase in stability, a 4-week healing time should be considered before orthodontic loading to improve stationary anchorage, beside that an increase in bone-to implant contact 2-8weeks after placement of (MIs) implants⁽²²⁾, so the increase in bone implant contact in this study research by about 12% can be considered a high enough within a short time of bone healing as a result of using the Ozonated Olive Oil. The differences in CBIC%, CBA% and CBT as compared with other studies could be relate to method of sectioning procedures staining types and level of stain which mainly influence the identification of maturation levels of bone⁽²³⁾.

REFERENCES

- [1] Reynders, R. M.&J. de Lange (2014). Moderate quality evidence that surgical anchorage more effective than conventional anchorage during orthodontic treatment. **Evid Based Dent**15(4): 108-109.
- [2] Oikarinen, K.;A. M. Raustia&M. Hartikainen (1995). General and local contraindications for endosseal implants--an epidemiological panoramic radiograph study in 65-year-old subjects. **Community Dent Oral Epidemiol**23(2): 114-118.
- [3] Cohen, A.&E. S. Horton (2007). Progress in the treatment of type 2 diabetes: new pharmacologic approaches to improve glycemic control. **Current Medical Research and Opinion**23(4): 905-917.
- [4] Oates, T. W.&G. Huynh-Ba (2012). Diabetes Effects on Dental Implant Survival. Forum implantologicum, NIH Public Access.
- [5] Agrillo, A.;P. Sassano;C. Rinna;P. Priore&G. Iannetti (2007). Ozone therapy in extractive surgery on patients treated with bisphosphonates. **Journal of Craniofacial Surgery**18(5): 1068-1070.
- [6] Lynch, E.;M. Grootveld;J. Holmes;C. SILWOOD;A. CLAXSON;J. Prinz&H. Toms (2003).H NMR Analysis of Ozone-treated Grapeseed, Olive, and Sunflower Seed Oils. 32nd Annual Meeting and Exhibition of the AADR.
- [7] Santrock, J.;R. A. Gorski&J. F. O'Gara (1992). Products and mechanism of the reaction of ozone with phospholipids in unilamellar phospholipid vesicles. **Chemical research in toxicology**5(1): 134-141.
- [8] Mostafa, B. M. Z. (2006). Evaluation of the Effect of Ozonized Water on the Periodontium of Normal & Diabetic Rats.
- [9] Frascino, A. V.;A. Mantesso;L. Corrêa&M. C. Z. Deboni (2013). Aqueous-ozone irrigation of bone monocortical wounds in hyperglycemic rats. **Acta Cirurgica Brasileira**28(5): 327-333.
- [10] Dubey, R. K.;D. K. Gupta&A. K. Singh (2013). Dental implant survival in diabetic patients; review and recommendations. **Natl J Maxillofac Surg**4(2): 142-150.

- [11] Ramazanzadeh, B. A.;K. Fatemi;M. Dehghani;N. Mohtasham;A. Jahanbin&H. Sadeghian (2014). Effect of healing time on bone-implant contact of orthodontic micro-implants: a histologic study. **ISRN Dent****2014**: 179037.
- [12] Freire, J. N.;N. R. Silva;J. N. Gil;R. S. Magini&P. G. Coelho (2007). Histomorphologic and histomophometric evaluation of immediately and early loaded mini-implants for orthodontic anchorage.**Am J Orthod Dentofacial Orthop****131**(6): 704.e701-709.
- [13] Barikani, H.;S. Rashtak;S. Akbari;S. Badri;N. Daneshparvar&A. Rokn (2013). The effect of implant length and diameter on the primary stability in different bone types.**J Dent (Tehran)****10**(5): 449-455.
- [14] Shadid, R. M.;N. R. Sadaqah&S. A. Othman (2014). Does the Implant Surgical Technique Affect the Primary and/or Secondary Stability of Dental Implants? A Systematic Review.**Int J Dent****2014**: 204838.
- [15] Mahesh, L.;T. Narayan;G. Kostakis&S. Shukla (2014). Periotest values of implants placed in sockets augmented with calcium phosphosilicate putty graft: a comparative analysis against implants placed in naturally healed sockets.**J Contemp Dent Pract****15**(2): 181-185.
- [16] Turner, P. S.&G. H. Nentwig (2014). Evaluation of the value of bone training (progressive bone loading) by using the Periotest: A clinical study.**Contemporary clinical dentistry****5**(4): 461.
- [17] Håkkelien, A. M.;J. C. Bryne;K. G. Harstad;S. Lorenz;J. Paulsen;J. Sun;T. S. Mikkelsen;O. Myklebost&L. A. Meza-Zepeda (2014). The regulatory landscape of osteogenic differentiation.**Stem Cells****32**(10): 2780-2793.
- [18] Cardemil, C.;P. Thomsen&C. Larsson Wexell (2015). Jaw Bone Samples From Bisphosphonate-Treated Patients: A Pilot Cohort Study.**Clinical implant dentistry and related research**.
- [19] El Hadary, A. A.;H. H. Yassin;S. T. Mekhemer;J. C. Holmes&M. Grootveld (2011). Evaluation of the effect of ozonated plant oils on the quality of osseointegration of dental implants under the influence of Cyclosporin A an in vivo study.**J Oral Implantol****37**(2): 247-257.
- [20] Erdemci, F.;Y. Gunaydin;M. Sencimen;I. Bassorgun;M. Ozler;S. Oter;A. Gulses;A. Gunal;S. Sezgin;G. R. Bayar;N. Dogan&I. K. Gider (2014). Histomorphometric evaluation of the effect of systemic and topical ozone on alveolar bone healing following tooth extraction in rats.**Int J Oral Maxillofac Surg****43**(6): 777-783.
- [21] Niedzwiedzki, T.&J. Filipowska (2015). Bone remodeling in the context of cellular and systemic regulation: the role of osteocytes and the nervous system.**J Mol Endocrinol****55**(2): R23-36.
- [22] Zhang, L.;Z. Zhao;Y. Li;J. Wu;L. Zheng&T. Tang (2010). Osseointegration of orthodontic micro-screws after immediate and early loading.**Angle Orthod****80**(2): 354-360.
- [23] Wong, Y. P.;S. A. Shah;N. Shaari;M. S. Mohamad Esa;I. Sagap&N. M. Isa (2014). Comparative analysis between multilevel sectioning with conventional haematoxylin and eosin staining and immunohistochemistry for detecting nodal micrometastases with stage I and II colorectal cancers.**Asian Pac J Cancer Prev****15**(4): 1725-1730.