

Diaphragmatic Pacing - A Presentation of Twiddler's Syndrome, A Case Report

Sandeep Kumar¹, Adil Ahmad Khan², Swati Singh³,
Srikant Behera⁴, Ayasa Parveen⁵

^{1,2,3}Senior Resident Cardiology, Jawaharlal Nehru Medical College, AMU, Aligarh, India

^{4,5}Postgraduate Student, Jawaharlal Nehru Medical College, AMU, Aligarh, India

ABSTRACT

Twiddler's syndrome, a rare but potentially lethal complication of cardiac pacemaker treatment, it is more common within the first year of implantation. It is characterized by device malfunction due to dislodgement of cardiac leads resulting from some form of manipulation by the patient [1]. In this report we present a patient who was presented with complain of abnormal abdominal pulsation after 3 month of permanent pacemaker implantation, she was diagnosed as a case of Twiddler's syndrome. In our case large surgical pocket and loose fixation of device with fascia lead to this complication.

Keywords: Diaphragmatic pacing, Twiddler syndrome.

INTRODUCTION

Bayliss in 1968 first described Twiddler's syndrome, a rare but potentially lethal complication of pacemaker treatment.[1] In this syndrome there is painless dislodgment of device leads resulting from the patient's manipulation of the implanted device. The majority of patients with this condition are diagnosed within the first year of implant.[2] As the leads move, they stop pacing the heart and can cause strange symptoms such as phrenic nerve stimulation resulting in abdominal pulsing or brachial plexus stimulation resulting in rhythmic arm twitching.[1]. In this report we present a patient who was presented with complain of abnormal abdominal pulsation, latter on diagnosed as Twiddler's syndrome within 3 months of implantation of the permanent pacemaker.

CASE REPORT

A 50 y old female was presented with complains of abnormal abdominal pulsation since 1 week. A permanent pacemaker VVI mode was implanted in right pre cordial area 3 month back for the complain of complete heart block. Her previous post pacemaker implantation chest X ray showed satisfactory position of device and ventricular lead (**Figure 1**), there was complete left bundle branch block (LBBB) pattern, fully paced rhythm on her previous post pacemaker implantation ECG. At presentation she was conscious and cooperative, her vitals was Pulse rate of 45/m irregular in character, Blood pressure of 130/86 mmHg, respiratory rate of 16/m, chest was clear, no pedal edema was present. At presentation ECG showed complete loss of pacing. Pacemaker interrogation showed increased pacemaker threshold to 5 mv. Chest X ray revealed rotation of pacemaker as compared to previous chest X ray along with dislodgment of ventricular lead from its position (**Figure 2**). The patient was immediately rushed to the pacing laboratory where a prophylactic temporary pacemaker was inserted. Fluoroscopy clearly showed the pulse-generator with twisted ventricular lead around it and dislodgment of ventricular lead. The pacemaker pocket was immediately reopened. The old ventricular lead was repositioned with an appropriate loop with good sensing and pacing parameters. The pulse-generator was fixed on the pectoral muscle with nonabsorbable suture. Postoperative hospital stay was uneventful and the patient was doing well in subsequent follow-ups. In our case there was no history of manipulation of device by patient.

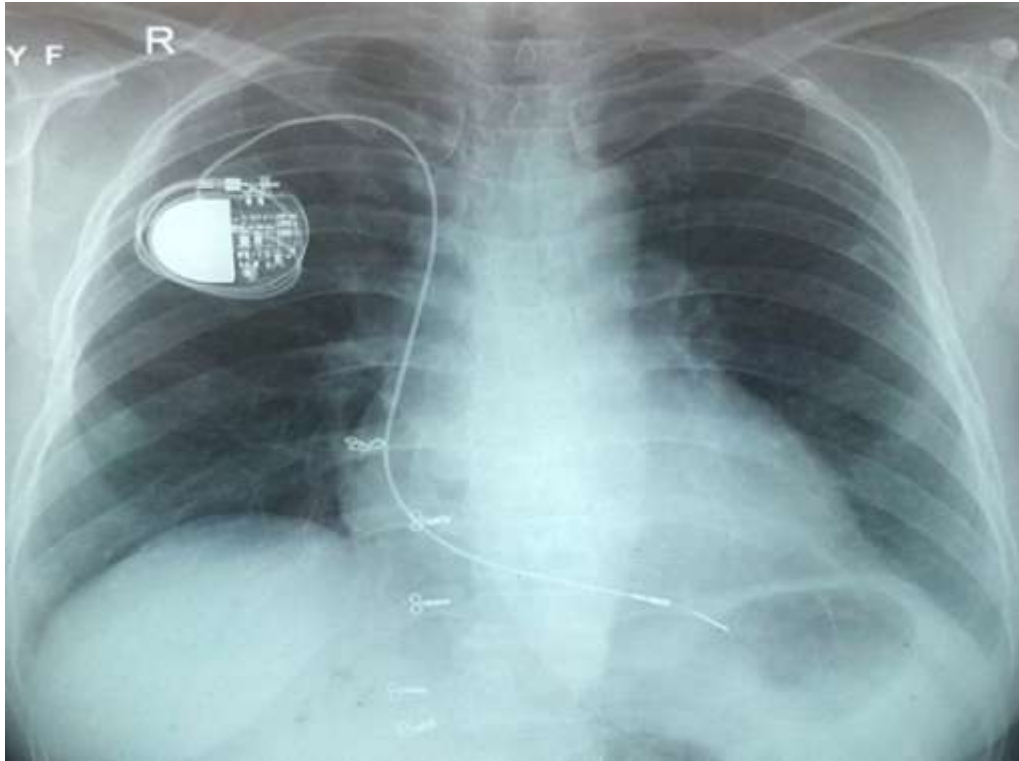


Figure 1- Previous (post permanent pacemaker implantation) chest Xray showing pacemaker implant in right pre cordial region with ventricular lead in right ventricle

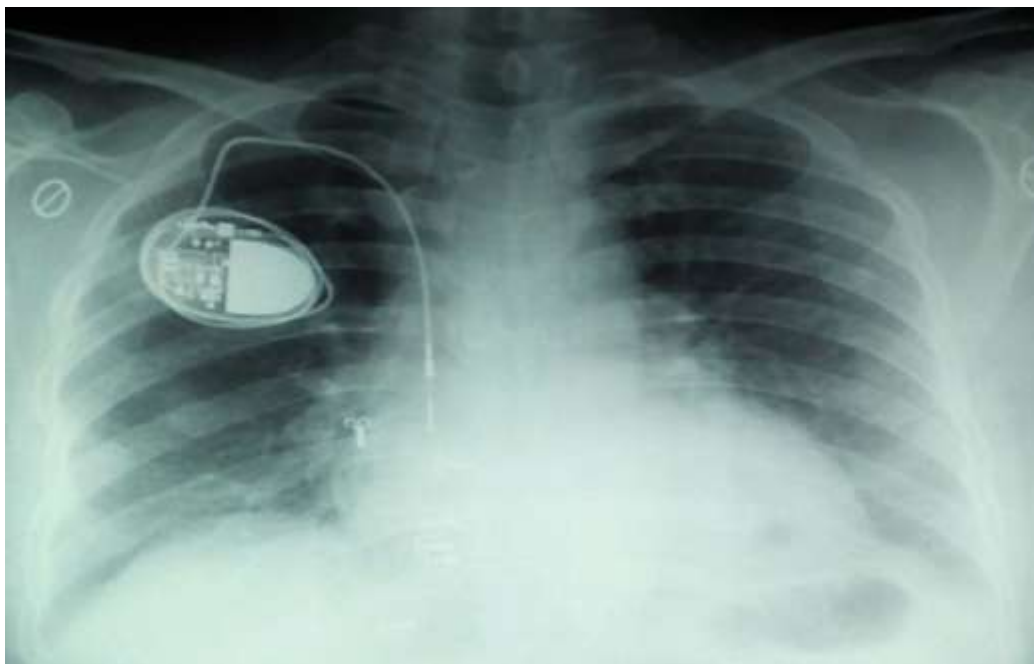


Figure 2 – chest X ray showing permanent pacemaker in situ in right pre cordial region which was rotated as compared with figure 1, along with ventricle pacing lead dislodgment from its previous position

DISCUSSION

First described in 1968, pacemaker twiddler's syndrome refers to permanent malfunction of a pacemaker due to the patient's manipulation of the pulse generator.[1] The reported frequency of Twiddler's syndrome is around 0.07-7%.[3,4]. The sequence of symptoms begins with the patient's deliberate or subconscious spinning of the pacemaker's pulse generator in a capacious pocket. The leads are dislodged, and ventricular pacing ceases. Subsequently, with continual reeling of the leads around the generator, the ipsilateral phrenic nerve is stimulated, resulting in diaphragmatic pacing and the sensation of abdominal pulsations as in our case . As the leads are further wrapped around the generator, rhythmic arm twitching occurs when the brachial plexus is paced. Risk factors for this condition include elderly age group, obesity, female gender, psychiatric illness, and the small size of the implanted device relative to its pocket.[3,5,6]. Most of the cases occur during the first year of pacemaker implantation but early Twiddler's used to occur within 48 h of permanent pacemaker implantation, late Twiddler's syndrome are also reported.[7,8]. The majority, like our patient, deny any history of manipulation of the device. [9]. Minimizing the pocket size and suturing the device to fascia generally prevent the development of this syndrome. The presence of heavy dressing also probably precluded him from any manipulation, other factors such as movement of the body may have also some role in this peculiar syndrome.

CONCLUSION

Twiddler's syndrome is a rare but catastrophic complication of permanent pacemaker implantation. There are many risk factors for it. Proper size pocket and active fixation of device and lead should always be performed to prevent this situation along with other preventive measures.

REFERENCES

- [1]. Bayliss CE, Beanlands DS, Baird RJ. The pacemaker-twiddler's syndrome: a new complication of implantable transvenous pacemakers. *Can Med Assoc J* 1968;99:371-373.
- [2]. Sharif M, Inbar S, Neckels B, Shook H. Twiddling to the extreme: Development of Twiddler syndrome in an implanted cardioverter-defibrillator. *J Invasive Cardiol.* 2005;17:195-6.
- [3]. Fahraeus T, Hijer CJ. Early pacemaker Twiddler syndrome. *Europace.* 2003;5:279-81.
- [4]. Hill PE. Complications of permanent transvenous cardiac pacing: A 14-year review of all transvenous pacemakers inserted at one community hospital. *Pacing Clin Electrophysiol.* 1987;10:564-70.
- [5]. Castilo R, Cavusoglu E. Twiddler's syndrome: An interesting cause of pacemaker failure. *Cardiology.* 2006;105:119-21.
- [6]. Gupta R, Lin E. Twiddler syndrome. *J Emerg Med.* 2004;26:119-20.
- [7]. Saroj Mandal, Arindam Pande, and Dhiman Kahali .A Rare Case of Very Early Pacemaker Twiddler's Syndrome. *Heart Views.* 2012 Jul-Sep; 13(3): 114-115.
- [8]. Dursun I, Yesildag O, Soylu K, Yilmaz O, Yasar E, Meric M. Late pacemaker Twiddler syndrome. *Clin Res Cardiol.* 2006;95:547-9.
- [9]. Nicholson WJ, Tuohy KA, Tilkemeier P. Twiddler's syndrome. *N Engl J Med.* 2003;348:1726-7.