

Early Orthodontic Treatment: Is the Benefit Worth the Burden?

Dr. Sandeep Kumar¹, Dr. Pranav Parashar², Dr. Sumit Kumar Yadav³
Dr. Mukesh Gupta⁴, Dr. Achla Bharti Yadav⁵, Dr. Supriya Bhandage⁶

¹Senior Lecturer, Dept. of Orthodontics & Dentofacial Orthopedics, Uttaranchal Dental and Medical Research Institute, Dehradun, Uttarakhand, India

²Senior Lecturer, Dept. of Oral & Maxillofacial Surgery, Index Institute of Dental Sciences, Indore, M.P., India

³Reader, Department of Orthodontics & Dentofacial Orthopedics, Mithila Minority Dental College & Hospital,, Darbhanga, Bihar, India.

⁴Senior Lecturer, Dept. of Orthodontics & Dentofacial Orthopedics, Index Institute of Dental Sciences, Indore, M.P., India

⁵Assistant Professor, Department of Oral Pathology, Post Graduate Institute of Dental Sciences, Pt. B. D Sharma University of Health Sciences, Rohtak, Haryana, India

⁶Assistant Professor, Dept. of Oral & Maxillofacial Surgery, Sri Hasanamaba Dental College, Vidyanagar, Hassan, Karnataka, India.

Abstract: The timing of orthodontic treatment to achieve an optimal outcome is an issue of paramount importance to clinical orthodontist. In providing orthodontic care for pediatric patients, clinicians often questioned whether to begin treatment early i.e. during the primary or early-transitional dentition or wait until all or most of the permanent teeth are present. The early treatment eliminates noxious habits, re-orientates dental-maxillary development and compensates for the structural discrepancy between teeth and bone. It would be interesting for a clinician to know what measures could be used in corrective or interceptive treatment to stop an unwanted development at an early stage and to ensure normal growth thereafter. The purpose of this article is to make the clinicians familiar with various issues of early orthodontic treatment.

Keywords: Early orthodontic treatment, Comprehensive treatment, Habits, Mixed dentition.

Introduction

Probably one of the most commonly asked questions by parents making inquiries to orthodontic clinics are “When should I bring my child in for an examination to see if he or she will need braces?” In the past, it was commonly believed that a patient should not consider visiting an orthodontist until age 12 or so, when all the permanent teeth have erupted. However, recent advances in early orthodontic treatment have made it advantageous for children suffering from some forms of orthodontic or dental jaw deformities to see an orthodontist for the first time by the age of 7 when the permanent first molars and incisors have erupted. Until the age of five, the main growth of a child’s head is the neurocranium or braincase. After age five the oral facial area of the child’s head becomes the dominant growth area with the emergence of the face from under the cranium or skull. Delaying treatment until age 12 will result in the loss of valuable growth potential for a large number of patients, especially females who are well into the last pubertal growth spurt by age eleven. An important consideration for early orthodontic treatment should be the face, due to the fact that the face has more visible structural disharmonies than any other part of the body. During the early phases of development of a child’s head and face, the bones and teeth are more readily adjusted allowing for an easier correction of any jaw and bite irregularities. The formation of these facial imbalances are not solely the result of abnormal growth and development due to genetics, but can also be the result of abnormal environmental factors such as mouth breathing, thumb sucking, tongue thrusting, etc. The conditions, if undetected until a later, may worsen and require a surgical procedure and the extraction of multiple permanent teeth to make the correction^[4].

Phases of Orthodontic Treatment^[3]

There are two phases of orthodontic treatment:

1. Phase I Treatment
2. Phase II Treatment

Phase I Treatment

Treatment initiated during primary or mixed dentition period with the purpose to prevent, intercept or correct specific orthodontic problems, also known as **early orthodontic treatment**. The early phase of treatment is usually started between the ages of 6 and 10, and may last 6 to 24 months. During recent years it has become increasingly popular.

Phase II Treatment

Treatment initiated during the permanent dentition with a comprehensive approach to correcting the orthodontic problems, also known as **comprehensive treatment**. The second phase of treatment is usually initiated when all of the permanent teeth have erupted and employs the placement of braces on the teeth.

Phase I Treatment (Early Orthodontic Treatment) ^[3]

Preventative Early treatment

It includes patient education and maintenance of a favorable orthodontic condition. (E.g. Patient education of stopping digit sucking habits, Space maintenance appliances)

Interceptive Early treatment

It includes improvement of an orthodontic problem. (E.g. Primary tooth guidance extractions, Reduction of excessive over jet, Growth modification appliances, Space redistribution, Space creation, Deep bite reduction, Habit appliances)

Corrective Early treatment

It includes complete or nearly complete correction of an orthodontic problem. (E.g. Cross bite correction, Growth modification, Alignment of anterior teeth)

As suggested by Gianelly, ^[9] the late mixed dentition offers the best time for intervention for several reasons:

1. The E space still exists.
2. Approximately 80% of the patients are still treatable by no extraction.
3. The treatment can be completed in one phase.
4. The orthodontist can still capitalize on growth.

The late mixed dentition approach offers many technical advantages; but there are some pecuniary reasons for waiting also. Before any first-phase commitment is made by the doctor, a definite therapeutic objective, time limitation, and treatment fee must be decided, and the family of the patient must thoroughly understand what these goals are. ^[6]

Goals of Early Orthodontic Treatment ^[3]

- Decreased potential for irreversible damage to dentition & supporting structures.
- Improved occlusal function
- Improved psychosocial development
- Improved or corrected skeletal discrepancies
- Phase II treatment simplification

Benefits of Early Orthodontic Treatment to Patients

1. Superior facial esthetics as it creates more pleasing arrangement of teeth, lips & face
2. Greater ability to modify the growth of jaws
3. Reduced extractions of permanent teeth
4. Reduction in the duration and difficulty of subsequent therapy as it guides permanent teeth into more favorable position.
5. Consistent and predictable elimination of phase II treatment
6. Improvement in patients self esteem
7. Reduction in the trauma risk to protruded front teeth
8. Greater patient cooperation
9. Elimination, if not reduction in chances of future jaw surgeries
10. Greater long term stability
11. Correction of harmful oral habits

Benefits of Early Treatment to Orthodontists

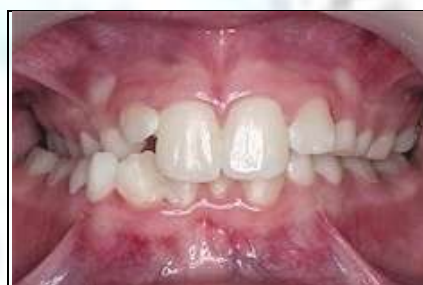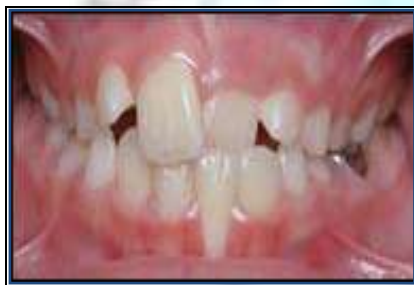1. Provides more treatment options.
2. Better use of growth potential.
3. Two shots at solving difficult or complex problems
4. Lesser need for different tooth movements, torque and dental compensation in the second phase of treatment.

Early Treatments with Proven Benefits

- Cross bite (Anterior & Posterior)
- Excessive Protrusions and Diastemas
- Skeletal and Dental Deep bite.
- Severe anterior or lateral open bite
- Crowding
- Ectopic Molars
- Cleft Palate Cases
- Supernumerary Teeth
- Serial Extractions
- Class II & Class III Malocclusions correction
- Incisor Trauma and Early Treatment
- Deleterious Oral Habits
- Psychological Benefits

Cross bite (Anterior & Posterior)

It may be due to Function shift of mandible or Narrow maxilla.



Posterior and anterior cross bites certainly merit early treatment. Not only for the functional improvement brought about by therapy but also for the improved esthetics that occurs with the anterior cross bite correction. These types of real occlusion are more easily treated in the mixed dentition than later, and early treatment also gives the clinician ample opportunity to see if relapse occurs. If the correction does not hold, there is still plenty of time and occasion for new intervention.^[6] Possible treatments of Cross bites are:

1. Removable expansion – slow expansion
2. Fixed expansion – slow/rapid expansion (Quad- Helix, W-arch, Rapid expansion (RPE))
3. Fixed treatment

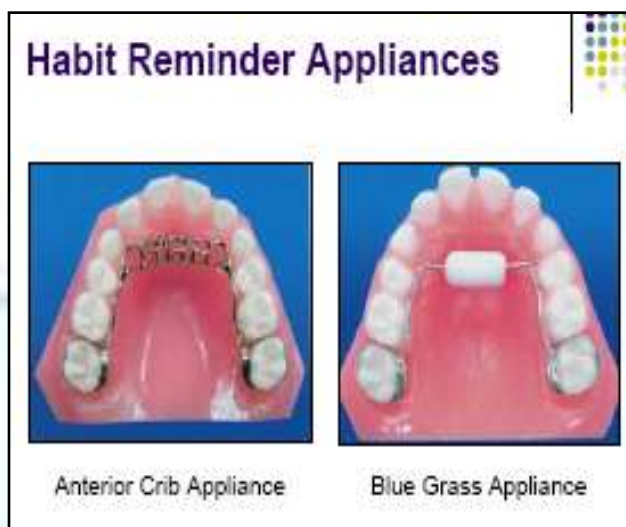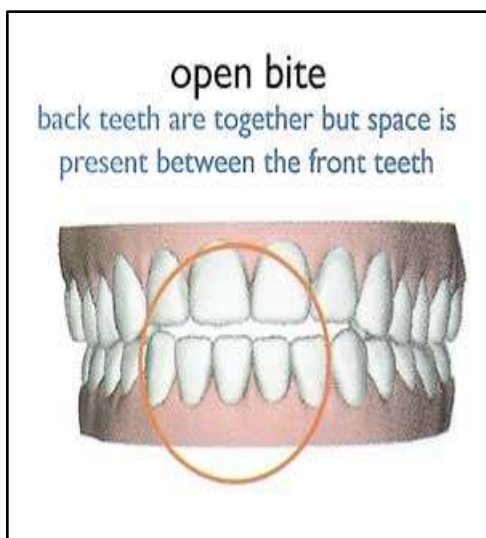
Early maxillary expansion treatment will remove the constraining influences on the mandibular arch and allow it to develop laterally. However with such treatment, the mandibular inter-canine width changes by less than 1mm

Ankylosed Teeth

Ankylosed teeth are another mixed dentition problem that needs orthodontic therapy because it seldom self-corrects. It is probably best not to treat this condition too early because space maintenance will usually be needed for several months or even years. Nevertheless, by the time the companion permanent tooth on the opposite side of the mouth is ready to erupt, the ankylosed tooth should be extracted and the underlying permanent tooth uncovered if necessary^[6].

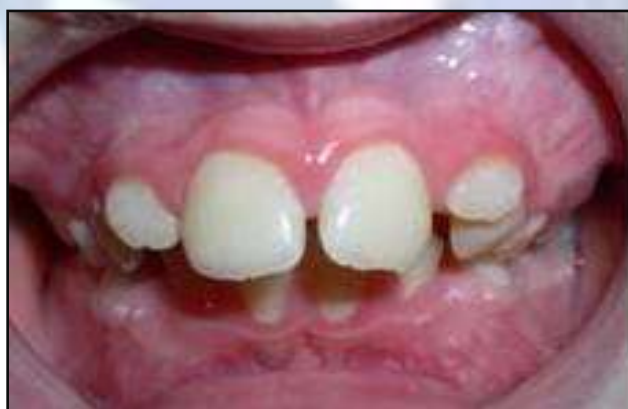Severe Anterior or Lateral Open bite

Severe anterior and lateral open bites should have early treatment and are often found accompanied by digit or tongue habits. Failure to completely eradicate these anomalies often leads to a lifetime of malocclusion that eventually becomes impossible to treat without the benefit of orthognathic surgery^[6] If there is a habit (e.g. prolonged thumb sucking) associated with the condition, the habit itself must be dealt with habit breaking appliance. If the habit is treated before the permanent anterior dentition erupts, the open bite may resolve spontaneously. If open bites are of true skeletal nature, they will require comprehensive treatment later on.^[7]



Excessive Protrusions and Diastemas

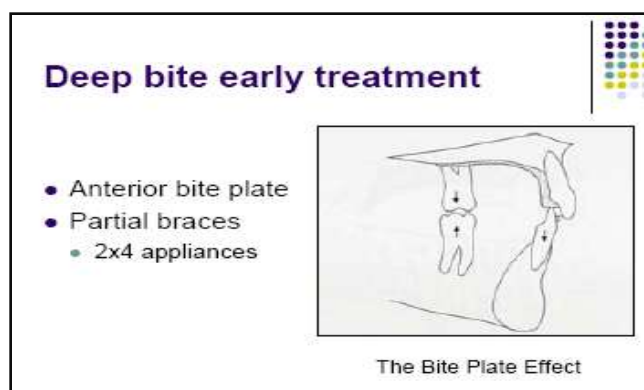
Excessive Protrusions and Diastemas that invite injury to lips or avulsions need treatment at an early age to avoid permanent damage to the dentition. Many times these maxillary maladies become self-perpetuating and invite entrapment of the lower lip that continues to hold the maxillary incisors apart and forward while simultaneously keeping the mandibular incisors lingually.^[6] This may affect the child's self-esteem as he/she get teased.



A fixed appliance therapy may be used to correct the protrusion or to close the diastema space. Maxillary fixed appliance may be combined with a headgear to correct excessive maxillary protrusion.

Skeletal and Dental Deep bite

Dental Deep Bite is due to extrusion of anterior teeth. Anterior bite plate and fixed early orthodontic treatment is needed for correction of deep bite.

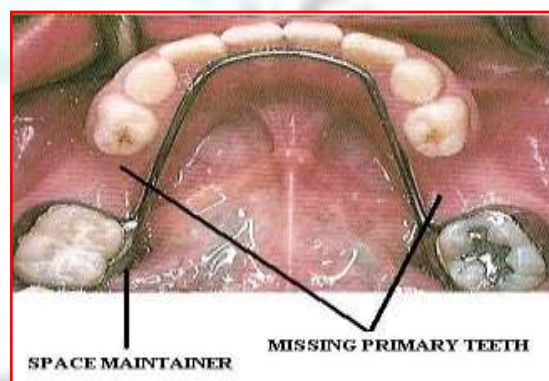
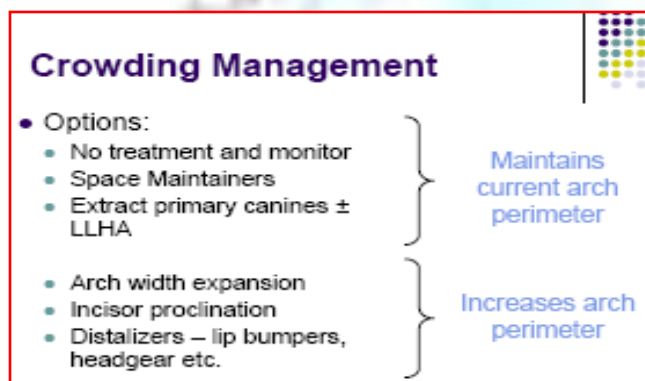


Skeletal Deep Bite is due to Lack of alveolar development & jaws over closure. Growth modification with functional & orthopedic appliances needed.

Crowding

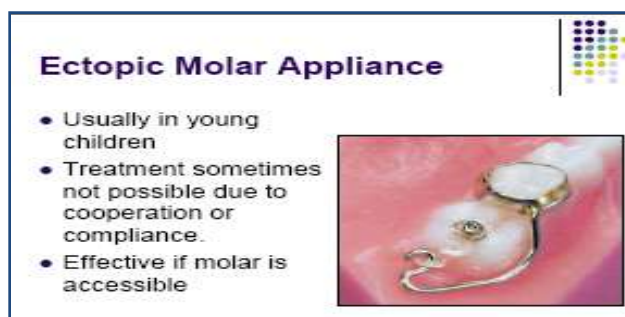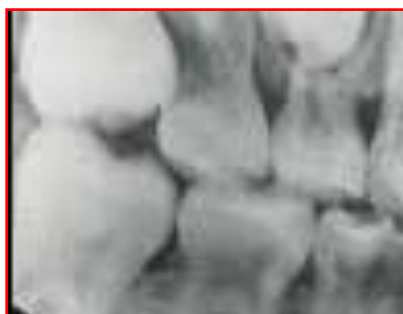Yet another reason for employing phase I treatment in growing patients is to correct arch length deficiencies. Early intervention in arch length discrepancies can eliminate the need for future premolar extractions. On the questions of what happens if nothing is done in the mixed dentition, the conclusion is that without treatment a short arch length will only get worse. The treatment options for correcting ALD problems in the mixed dentition are

- Preserve the existing arch length by holding appliances such as lingual arches
- Expanding the arches to accommodate larger permanent teeth
- Serial extraction to alleviate the crowding



Ectopic Molars

They are best treated when they are discovered e.g. ectopic eruption of maxillary first molars in a six year child. If left untreated for longer period, ectopic molar eruption may lead to early primary molar loss as well as reduction in arch length needed for permanent dentition^[6]

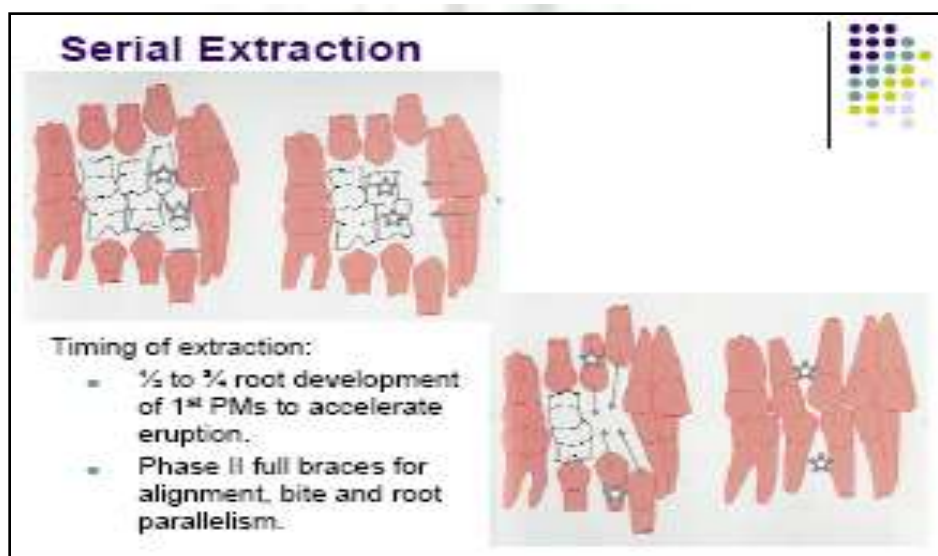


Cleft Palate Cases

Patients with cleft palates often need orthodontic therapy from the time of birth to allow them to take nutrition without milk escaping from their noses. These patients require continual orthodontic supervision and care until all of their Surgeries, Orthodontic arrangements, and Restorative needs are completed. It is not at all unusual to begin orthodontic therapy the day these children are born and not finish until late adolescence^[6]

Serial Extraction

It is the planned sequence of tooth removal during transition from primary to permanent dentition to promote eruption of teeth & reduced severity of crowding. When severe arch length discrepancies are found in the mixed dentition and it is clear that bicuspid extractions are needed for resolution, those removals can often be done several months before active therapy is planned. This allows semi-impacted cuspids to start a distal drift and erupt in a position that will make eventual treatment quicker and more effective^[6].



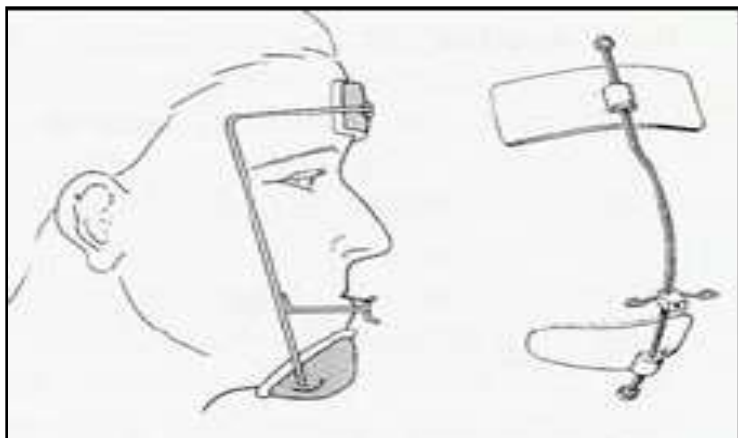
Serial extraction, if successful, would still necessitate comprehensive orthodontic treatment but with less burden.

Class III Malocclusion

Pseudo Class III Malocclusions should be treated before it develops into a true Class III malocclusion. Pseudo Class III patients that present with malocclusions that are more dental in nature than skeletal are often amenable to early intervention. If the malocclusion is a borderline case, sometimes opening the vertical dimension will rotate the mandible down and back and correct dental Class III without a deleterious effect on the patient's appearance. Early treatment also allows the orthodontist to monitor the development of these patients and make subsequent interventions at appropriate times should any feature of the correction relapse^[6].

True Class III Malocclusions due to a maxillary retrusion; such Class III malocclusion are probably best handled during the mixed dentition stage because osseous tissues are best modified during the times when rapid growth is occurring^[6] i.e. between the ages of 8-10; time when maxilla is undergoing active growth which can be modified to the patient's advantage. True Class III Malocclusion due to mandibular prognathism ;The treatment of such Class III abnormalities is straightforward, and is more efficacious if applied early, on deciduous dentition before age 6 years. The maxilla, repositioned correctly, grows together with the mandible^[2]

Two modalities that are used in phase 1 treatment for patients with Class III growth tendency are the chin cap and face mask/palatal expansion therapy. Delaire's type of face mask is effective in such patients who have a maxillary deficiency or mandibular prognathism, correction are supposed to occur by a combination of skeletal and dental movement. The maxilla moves downward and forward, while the mandible rotates down and back.



The late primary and early mixed dentition may be the most optimal treatment time. Current studies examining post treatment growth are of short duration and longer follow up is necessary to assess long-term benefits'

Class II Growth Modification

Skeletal Class II abnormalities are defined as those in which the maxilla is overhung relative to the mandible. They can be of maxillary, mandibular or mixed origin. In children, Class II abnormalities are often due to locked mandibular growth. There are three types of lock: functional, mechanical and psychological. Incisor over jet, a transverse deficit of the maxillary arch, and a distopalatine rotation of the maxillary molars are examples of mechanical locks that give the mandible a permanent retro position. It is thus important to remove these locks early on to permit free mandibular growth. Two facts justify early care for Class II abnormalities. The first is that the tissues of the craniofacial complex tend to respond more readily in young subjects. The second is that young patients cooperate better than older ones. The benefits of early treatment of Class II abnormalities are numerous: e.g. the prevention of trauma to the maxillary incisors by overcorrection of overhang, the interception of worsening malocclusion, and better psychological and social integration of the child. It has also been reported that the correction of Class II malocclusions improves orofacial functions^[2]

Cervical Headgear is ideally recommended in individuals who exhibit maxillary prognathism and have a low facial height. High Pull Headgear is prescribed in patients with maxillary proganthisam and increased facial height Functional regulator was introduced by Frankel and popularized by Mcnamara comparing cervical headgear and FR II in treating growing Class II patients Mcnamara et al reported that FR II had a great effect on mandibular length Twin block appliance is currently the most popular functional appliance. Twin block appliance significantly reduced over jet primarily by distal tipping of the maxillary incisors and proclination of the mandibular incisors. The increase in anterior and posterior facial height measurements was greater than the changes in mandibular length. This large vertical effect allows more dental compensation and along with the forward mandibular position provided correction of the class II skeletal pattern. To address hereditary forms (maxillary overjet or mandibular underjet), early treatment consists is fitting an activator of mandibular growth sometimes associated with an extraoral force^[2]

Incisor Trauma and Early Treatment

Early orthodontic treatment specifically designed to reduce over jet can affect the incidence of maxillary incisors trauma in children. In patients with increased over jet due to maxillary dent alveolar protrusion, early orthodontic treatment with a 2 x 4 appliance or Hawley's appliance can be started shortly after the eruption of the central incisors at approximately at the age of 7years to reduce over jet

Deleterious Oral Habits

Such as finger, thumb or lip sucking, tongue thrusting and mouth breathing must be intercepted during early age with habit braking appliances, otherwise they can cause bizarre malocclusions^[1]

Psychological Benefits

A final but often overlooked reason to begin early treatments is for the patient's psychological well-being. It is essential that a child develop a positive self-image in order to properly interact with other children. Deformities of the face and mouth can have severe negative psychological effects on the overall development of a child's personality due to their physical appearance as well as having adverse affects on their ability to speak correctly, often making even the brightest

child feel inadequate and lack confidence to achieve at the same level as his friends. Children who receive early orthodontic treatment have higher self concepts and more positive childhood experiences than those who do not have early correction of their malocclusions^[4]

Exceptions to Early Orthodontic Treatment^[6]

1. Clinicians need to recognize that although orthopedic appliances used for class II correction appliances can favorably modify the occlusion, there is abundant evidence that they are incapable of significantly augmenting or limiting the size of the mandible, even though they may alter mandible shape and its relationship to the maxilla.
2. One idea that continues to fascinate orthodontists is that of expanding the mandible to accommodate all of the teeth assigned to it. This has led to aggressive lip bumper therapy as well as other forms of therapy to increase mandible size. Nevertheless, studies by Little et al.⁶ strongly indicate that expectations of more than 1 mm increase in arch length may be too optimistic, particularly over the long term.
3. Early intervention in obvious bimaxillary protrusions with severe arch length discrepancies also seems presumptuous in that extraction of teeth will inevitably be carried out later in therapy. In these types of cases, one phase of treatment reserved for the permanent dentition would probably be a more sensible approach, and one that would not subject the patient to an overly extended treatment time. Finally, early orthodontic intervention is often limited by patients whose maturity, mouth size, or sensitivity threshold is inadequate for the planned therapy.

Limitations of Early Orthodontic Treatment

1. Longer overall treatment time.
2. Patient burnout or Loss of patient's compliance
3. Greater risks due to prolonged treatment are root resorption, white spot lesion, bone loss, increased caries, oral hygiene loss.
4. Increased cost
5. Dilacerations of roots
6. Impaction of maxillary canines by premature up righting of the roots of lateral incisors, Impaction of maxillary second molars.
7. Misdiagnosis

The late mixed dentition approach offers many technical advantages; but there are some pecuniary reasons for waiting also. Before any first-phase commitment is made by the doctor, a definite therapeutic objective, time limitation, and treatment fee must be decided, and the family of the patient must thoroughly understand what these goals are. The urgency of having definite time constraints and therapeutic goals for first-phase patients have the following benefits^[6]

- To prevent an unnecessarily extended treatment
- To prevent patient burnout
- To reduce jeopardy of oral tissues
- To allow achievement of specific and limited treatment goals
- To avoid becoming a two-phase treatment for one small fee.

Without a definite time and fee limitation for the completion of a first-phase treatment, there is the risk of the first-phase running into a second-phase almost before the doctor realizes it. At this point the doctor will have the unpleasant task of explaining to the parents why a second fee is necessary and trying to make them happy about an extension of fee and services they may find astonishing^[6]

Conclusion

Early treatment orthodontic procedures are relatively simple and inexpensive treatment approaches that target developing malocclusions during the mixed or deciduous dentition^[2]. First-phase or early orthodontic treatments offer many advantages to both doctor and patient, and these various therapies need to be part of every orthodontist's armamentarium^[6]. Early treatment is no simpler: on the contrary, it has to be based on an overall analysis of the patient's condition, and so requires thorough knowledge of human growth, the physiology of the orofacial functions, the morphogenesis of the dental arches

and child psychology. Best allies of the orthodontist in early treatment are time and growth that are allowed to express themselves with proper care^[5].

Sometimes the first phase of treatment can eliminate the need for a second phase, but this is rare. The early phase of treatment will correct some skeletal and facial problems and reduce the severity of others, but will not eliminate all these problems since most of the permanent teeth are still unerupted. It is the second phase that the final details of tooth position and bite relationships are established^[4]. Early treatments in orthodontics do not produce finished orthodontic results without a second phase of treatment in the permanent dentition. But several studies have suggested that systematically planned interceptive treatment in the mixed dentition might contribute to a significant reduction in treatment need between the ages of 8 and 12 years, often producing results so that further need can be categorized as elective.^[2] When majority of facial growth has ceased, the treatment options become limited. It is important to remember that early treatment allows us to obtain results, which would be impossible if intervention was postponed until a later age. Often the early phase of treatment will allow a patient to be treated without the need for extraction of permanent teeth, which otherwise would have resulted in a less pleasing facial appearance^[4]. Early treatments often fail to remedy anomalies entirely, but they greatly simplify subsequent orthodontic treatment.

References

- [1]. Prasad Narayana P et al. Timing of Orthodontic Treatment. J Oral Health Comm Dent 2011;5(2)94-96.
- [2]. Lahcen O, Laila L. Early Treatments in Orthodontics; Principles in Contemporary Orthodontics. Nov. 2011; Pages 251-276.
- [3]. Kearns Mark J. Early Treatment Orthodontics-Minium and Kearns [Internet]. Available from: <http://www.mknortho.com/portals/0/early%20orthodontic%20treatment.pdf>
- [4]. Williams M. Advantages of Early Orthodontic Care [Internet]. Available from: <http://www.dynaflex.com/pdf>
- [5]. Arvystas Michael G. Rationale for early orthodontic treatment. Am J Orthod Dentofacial Orthop 1998; 113(1):15-18.
- [6]. White L. Early orthodontic intervention. Am J Orthod Dentofacial Orthop. 1998; 113(1) : 24-28.
- [7]. Milos L. True benefits of early orthodontic treatment [Internet]. Available from: <http://www.childrendentalworld.com>
- [8]. Seminars in Orthodontics. Volume 11, Issue 3, Pages 111-170 (Sept. 2005).
- [9]. Gianelly AA. One-phase versus two-phase treatment. Am J Orthod 1995; 108:556-559
- [10]. Gianelly AA. Treatment of Crowding in the Mixed Dentition. Am J Orthod Dentofacial Orthop 2002; 121(6):569-571.