International Journal of Enhanced Research in Medicines & Dental Care (IJERMDC),
ISSN: 2349-1590, Vol. 4 Issue 10, October-2017, Impact Factor: 1.338

Grade V Renal Trauma Following Animal Attack: A Case Report

Arun Singh*[1], Sujit Kumar[2], Akhilesh Pandey[3]

ABSTRACT

Blunt abdominal trauma is routinely encountered in emergency department. About 10% of all patients have urogenital injuries. The treatment of renal trauma is still controversial but conservative management is increasingly accepted and preferred now a days in most renal injuries. Here we are presenting case of a young male who sustained Grade V renal trauma following an attack by bull. Nephrectomy was done. Post operative period was uneventful.

Keywords: Kidney, Nephrectomy, Trauma, Blunt abdominal trauma

INTRODUCTION

Following blunt trauma urinary system is injured in approximately 10% cases **[1].** The most common urological organ injured after trauma is kidney **[2].** Blunt renal trauma is more common than penetrating renal trauma comprising 60-95% of renal trauma cases. Renal trauma is classified according to 1989 American Association for Surgery of Trauma (AAST) grading system. This was revised in 2011 (TABLE 1) to report Grade V injury as purely vascular / pedicle injury **[3].** Management of renal injury often directly relates to the grade of injury as diagnosis. Over the last decade there has been a trend towards conservative management of high grade injuries, which helps in preserving renal function.

CASE REPORT

31 yrs young male patient was brought to Emergency department of Max Superspeciality Hospital, Gurugram (India) with alleged history of trauma following an attack by bull. Patient described an injury sustained over right flank following an attack by bull. There was no history of loss of consciousness, vomiting, any ENT bleeding or seizure. Patient had no other significant medical or surgical history. On arrival patients airway was patent, HR – 94/min, BP-100/90mmHg, RR-18/min, Chest showed bilateral equal air entery, Abdominal examination showed Fullness and bruise over right flank. Tenderness was present over lower abdomen. Upper and lower extremity had no injury. Foley's catheter was placed, urine was clear. Laboratory values showed Hb – 12.4gm%, TLC – 8600/ml, Platelet – 3,76,000/ml, Urea/ Creatinine –26/0.9 mg/dl, PT/INR within normal limits. Patient was hemodynamically stable. FAST scan was positive hence CECT abdomen was done which showed completely avascularised right kidney with large right perinephric haematoma, no contrast extravasations was found (Figure 1).

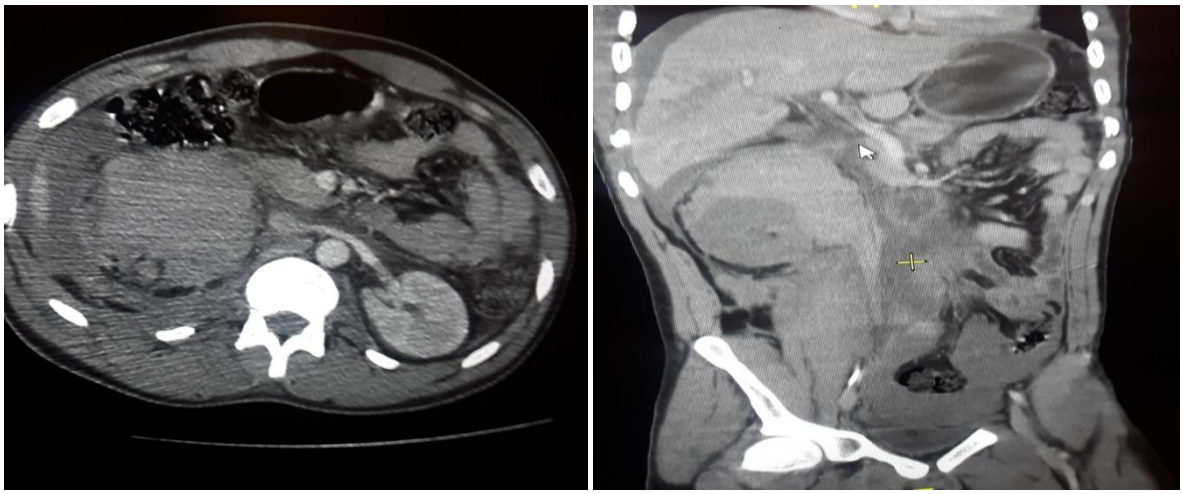

Fig : 1A **Fig : 1B**

(Figure 1A/1B showing completely avascularised right kidney with large right perinephric haematoma)

Patient was kept under observation and intensive monitoring was done by vitals charting, intake/ output charting, serial physical examination and laboratory test. After 2 hours patient showed tachycardia (Pulse 130/min) and fall in blood pressure (BP – 80/60 mmHg), Hb 8.9gm%, abdominal distension was present. Due to failure of non operative management patient underwent exploratory laparotomy with right nephrectomy. Post operative period was uneventful.

DISCUSSION

Kidney is the most commonly injured organ in genitourinary system following blunt abdominal trauma. Blunt injury is commoner form of injury. As with all trauma cases a systematic approach following the principle of advanced trauma life support (ATLS) should be applied, ensuring that airway, breathing and circulatory dysfunctions are assessed and treated appropriately in the first instance**[4**].

Table 1: AAST Classification f Renal Injuries

Grade	Type of Injury	Description
I	Normal contusion Hematoma	Microscopic or gross hematuria with normal urologic findings Nonexpanding subcapsular hematomas with no laceration
II	Hematoma Laceration	Nonexpanding perinephric (perirenal) hematomas confined to the retroperitoneum Superficial cortical lacerations less than 1 cm in depth without collecting system injury
III	Laceration	Renal lacerations greater than 1 cm in depth without collecting system injury
IV	Laceration Vascular injury	Renal lacerations extending through the renal cortex, medulla, and collecting system Injuries involving the main renal artery or vein with contained hematoma, segmental infarctions without associated lacerations
V	Laceration Vascular injury	Shattered kidney, ureteropelvic junction avulsions Complete laceration (avulsion) or thrombosis of the main renal artery or vein that devascularizes the kidney

AAST grading system prospectively validated and is directly associated with the need for surgical management. In renal trauma patients AAST can be applied as a predictor of outcome. CT Scan remains the gold standard investigation of renal trauma where the patient stability allows. Angiography can be useful in localising vascular injury and thus helping to target intervention**. [5,6]**. Indication of surgery in renal trauma cases are – Patient who remains hemodynamically unstable despite resuscitation with crystalloid and blood products, with likely haemorrhage and expanding retro peritoneal hematoma.

Grade I and Grade II renal injuries generally managed conservatively - ranges from rest and analgesics to monitoring of vital signs [**5]**. Historically surgical management of grade III renal injury has been controversial but current evidence favours conservative management [**7**]. Around one quarter of grade IV renal injuries are managed conservatively **[5**]. Grade IV renal trauma has poor outcome in terms of renal function.

Previously renal trauma has been regarded as an absolute indication for exploration however an increasing number of reports suggest that parenchymal grade V injured patient who are hemodynamically stable can be managed conservatively [**8]**. Absolute indication for immediate renal exploration are expanding perirenal hematoma or circulatory instability of patient. Children are more vulnerable to renal artery injury in blunt trauma. This is attributed to relatively larger kidneys in the paediatric population, their higher mobility and relatively lack of surrounding protective tissue **[9].** Emergency Nephrectomy remains the gold standard treatment for acute uncontrollable renal hemorrhage **[5,10].**

CONCLUSION

We present an interesting case of grade V kidney injury due to an animal attack. FAST scan was positive, CT Abdomen showed completely avascularised right kidney with large right perinephric haematoma. Patient remains hemodynamically unstable despite resuscitation with crystalloid and blood products, Exploratory laparotomy with nephrectomy was done after initial conservative management. Post op period was uneventful. Animal-related traumas are a significant medical problem due to their serious potential to cause morbidity and mortality.

REFERENCE

[1]. Bent C, Iyngkaran T, Power N, Matson M, Hajdinjak T, et al. (2008) Urological injuries following trauma. Clin Radiol 63: 1361-1371.
[2]. Tait CD, Somani BK (2012) Renal trauma: case reports and overview. Case Rep Urol 2012: 207872.
[3]. Buckley JC, McAninch JW (2011) Revision of current American Association for the Surgery of Trauma Renal Injury grading system. J Trauma 70: 35-37.
[4]. Eastham JA, Wilson TG, Ahlering TE (1992) Radiographic evaluation of adult patients with blunt renal trauma. J Urol 148: 266-267
[5]. Hohenfellner. *Guidelines on Urological Trauma*. European Association of Urology Guidelines; 2009.
[6]. American College of Surgeons Committee on Trauma. *Advanced Trauma Life Support For Doctors*. 8th edition. Student Course Manual; 2008.
[7]. Thall EH, Stone NN, Cheng DL, et al. Conservative management of penetrating and blunt Type III renal injuries. *British Journal of Urology*. 1996;77(4):512–517
[8]. Hotaling JM, Wang J, Sorensen MD, et al. A national study of trauma level designation and renal trauma outcomes. J Urol 2012 Feb;187(2):536-41.
[9]. Fraser JD, Aguayo P, Ostlie DJ, St Peter SD: Review of the evidence on the management of blunt renal trauma in pediatric patients. Pediatr Surg Int, 2009; 25: 125–32
[10]. Alsikafi NF, Rosenstein DI. Staging, evaluation, and nonoperative management of renal injuries. *Urologic Clinics of North America*. 2006;33(1):13–19.

Conflict of interest - None declared
Funding sources - None