

The Efficiency of Ultrasound and Doppler Ultrasound in Differential Diagnosis of periapical lesions in Iraqi populations

Shahrazad Sami Saeed¹, Usama Morad Ibraheem², Manar Mudhafar Alnema³

Oral & Maxillofacial Surgery / College of Dentistry / University of Mosul / Iraq

ABSTRACT

Aim of study: To evaluate the efficiency of ultrasound with color Doppler ultrasound in differential diagnosis of periapical lesions.

Subjects Material and Methods: Twenty six patients aged between 8-40 years classified as age groups: Group 1 from 8-18 years, Group 2 from 19-29 years, Group 3 from 30-40 years and with periapical lesion in maxillary and mandibular anterior teeth and premolars diagnosed by their clinical sign and symptoms and radiographic findings who attended to the maxillofacial unit in al Al Jamhori Teaching Hospital and Specialist Center of Dentistry/Right in Mosul city were include in this study. Ultrasonographic examinations were performed and, according to the ultrasonography findings, lesions were classified into four groups: granuloma, radicular cyst, abscess and phoenix abscess. Additionally, color Doppler ultrasonography examinations were performed to evaluate blood flow in all patients. After the ultrasonography examination, the patients underwent surgical treatment. The correlation between ultrasonography and Doppler ultrasonography findings of the lesions and histological findings was investigated.

Result: In all cases it was possible to differentiate between cyst, abscess granuloma and granuloma with acute exacerbation (phoenix abscess) by using ultrasound with color Doppler ultrasound and it was also possible to measure the lesions, to evaluate their content and to evaluate their vascularization in the anterior part of the upper and lower jaws and premolars teeth. A accuracy percentage, sensitivity percentage and specificity percentage for each type of periapical lesion also determined.

Conclusion: Ultrasound as a reliable diagnostic technique for differentiating periapical lesions.

Key words: periapical lesions, ultrasound, histopathological results.

INTRODUCTION

Periapical lesions are the most common pathologic conditions that develop in the root tip of a non-vital tooth. These lesions are infectious and exhibit a difference in clinical and radiographic manifestations^{1,2,3}

A proximity 90% of the periapical inflammatory lesions, clinically and radiologically diagnosed are belong to the groups of periapical granuloma, periapical cyst and periapical abscess. Nevertheless, a range of other lesions caused by developmental, metabolic, odontogenic or neoplastic disorders that greatly similar the inflammatory processes on radiographs can be demonstrate in the periapical region²

The periapical lesions are usually asymptomatic and are discovered during routine radiographic examination, sometimes after having become quite large. Histopathological categories of periapical lesion referred to as apical periodontitis^{4,5,6,7}

Apical periodontitis represents as an inflammatory immune response of periradicular tissues to the progression of microorganism from an infected root canal space to the periapical area that lead to demineralization of bone and bone resorption^{8,9,10,11,12}

It is a multifactorial inflammatory disease that is resultant of the interaction of numerous host inflammatory cells and bacterial factors¹³

Bacteria, their metabolic products and debris of infected pulp tissues remaining in lateral canals, dentinal tubules or gaps between the root canal and root filling materials consider the major ethological factors of apical periodontitis¹⁴.

Virus regard as one of etiological agents that participated in the pathogenesis of apical periodontitis and currently use of polymerase chain reaction method to detect herpes viruses in periradicular lesions has suggested that some herpes viruses, particularly human cytomegalovirus (HCMV) and Epstein-Barr virus (EBV) can contribute in the pathogenesis of the apical periodontitis^{15;16;17;18;19;20}

Ultrasonography” means imaging with ultrasound; “ultra” means beyond or in excess; “sound” means audible sound energy so the term of sonography means the form of sound energy beyond audible range^{21;22}

Ultrasound real time imaging has numerous application in several diagnostic fields of medicine. It is relies on the phenomenon of reflection of ultrasound waves (echoes) at the interface between two tissues that have different acoustic impedance²³

The phenomenon of ultrasound occur as a result of periodic change in the pressure of air against the eardrum. The periodicity of these changes positioned between 1500 and 20,000Hz, more precisely ultrasound has a periodicity greater than 20 kHz, greater than the audible range. The clinical application of ultrasound uses vibratory frequency in the range of 1-20MHz²⁴

Scanner used for sonography produce electrical impulse that are change into ultra-high frequency sound wave by a transducer that can change the electrical energy into sonic energy²⁸

Piezoelectric crystal of transducer is made up of huge number of dipoles arranged in a geometric pattern. A dipole may be thought of as a distorted molecule that appear to have a positive charge on one end and negative charge on the other. The electrical impulse produce by the scanner cause the dipoles in the crystal to arrange themselves with the electrical field and thus cause sudden change in the crystal's thickness. This suddenly change starts a series of vibration that are transmit into the tissue being investigated²⁴

As ultrasound energy is pass through tissue is attenuated by combination of reflection, scattering, refraction and absorption, some of the reflected ultrasound returns to the probe to be converted back to electrical energy. This electrical information is processed by the system's computer to ultimately produce the sonographical image²⁹

By measuring reflected waves(echoes), it is possible to determine the objects' size, shape and nature. The image is produced relied on the amplitude (loudness), frequency (pitch) and time it takes for the ultrasound signal to return from the area of the patient being examined to the transducer, as well as the composition of body tissue through which and the kind of body structure the sound travels through. Data are shown as two dimension vector of pixels (picture elements) whose intensity is represented on a grey-scale: position and grey value correspond to echo source and amplitude²⁶

Recent techniques allow echoes to be processed at a sufficiently rapid rate to permit perception of motion; this technique is known as real time imaging²⁴

Doppler ultrasound are non invasive technique that can be utilize to examine movement and particularly evaluate blood flow in arteries and veins, it also can be employed to supply information considering the perfusion of blood flow in organ or inside the area of interest²⁵

The movement of blood cells causes a change in pitch of the reflected sound waves (called the Doppler effect). A computer collects and processes the sounds and creates graphs or color pictures that represent the flow of blood through the blood vessels²⁶

Cotti et al., in 2003 proposed that ultrasound may help to make a differential diagnosis between cysts and granulomas by revealing the nature of the content of a bony lesion²⁷

MATERIAL AND METHODS

Twenty six patients aged between 8-40 years classified as age groups: Group 1 from 8-18 years, Group 2 from 19-29 years, Group 3 from 30-40 years and with periapical lesion in maxillary and mandibular anterior teeth and premolars diagnosed by their clinical sign and symptoms and radiographic findings who attended to the maxillofacial unit in Al Jamhori Teaching Hospital and Specialist Center of Dentistry/Right bank in Mosul city were include in this study. Informed consent was taken from all the patients before their inclusion in the study. A special patients record sheet was formulae to record the history, clinical examination, radiographic findings, ultrasound examination and histopathological examination.

Conventional Periapical Film Radiographic Examination:

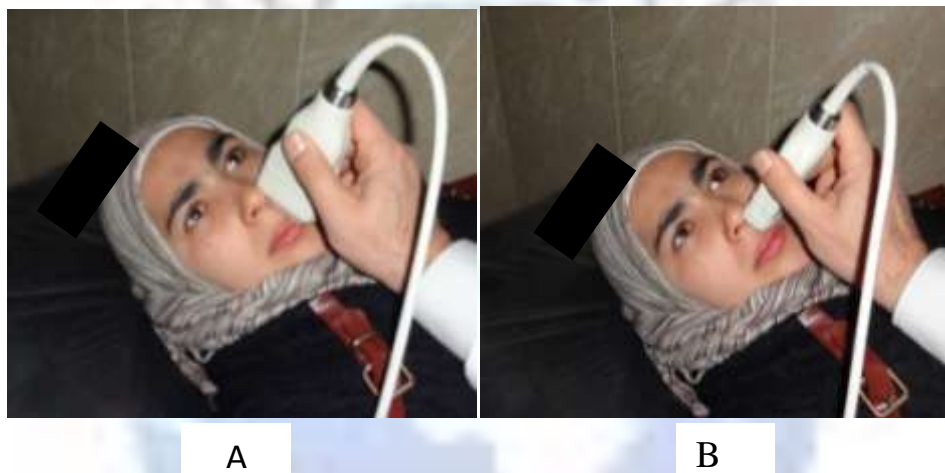The periapical radiograph for all twenty six patients had taken by bisecting angle technique. Dental x-ray unit (68kVp,8Ma, 2 mm filtration) and Kodak E-speed used to take the periapical radiograph. This technique involve that the appropriate sized film packet(size 2), is positioned and orientated in the mouth with about 2 mm extending beyond the incisal or occlusal edges, to ensure that all of the tooth will appear on the film. The patient is then asked to gently support the film packet using either an index finger or thumb keeping the film as close to the teeth as possible. The central x-ray beam is directed perpendicular to the imaginary bisector that bisects the angle formed by long axis of the tooth and the film. The imaginary bisectors creates two equal angles and provides a common side for the two imaginary equal triangles, the two imaginary triangles are right angles and are congruent. The conventional radiographs

were then processed automatically in fresh chemicals, the radiographs were viewed and evaluated on a viewing box under normal operating illumination and the surgeon specialist in maxillofacial unit were asked to make a detailed description of periapical lesion.

Ultrasound Examination

An ultrasound examination was then performed using the diagnostic ultrasound machine, H D11 XE (Philips Medical System, Japan), with color Doppler function, incorporating a high definition, multifrequency, 40 mm linear foot print, ultrasonic Probe operating at a frequency of 3-12 MHz . The ultrasound probe covered with a layer of ultrasound gel(ultrasonic transmission gel. Larser poortweg 26.8218 NK Leiystad). The probe was positioned outside the mouth on the skin overlying the periapical area. The probe position was changed several times in order to obtain an adequate number of transverse scans (axial plane) to define the bony defect. Longitudinal scans (sagittal plane) were also obtained. Where possible, the ultrasound probe was also positioned intraorally in the buccal sulcus overlying the apical area of the infected tooth. Transverse and longitudinal scans were obtained.

However, in some patients, intraoral scanning was not possible because the vestibule was too shallow. The thin anterior buccal bone and possible fenestration allowed ultrasound images to be obtained in all cases and the echo characteristics (hypoechoic/anechoic) of the apical lesions to be determined. Color Doppler was applied to each examination to detect blood flow.



Figure(1): Ultrasound examination of maxillary incisors; A: longitudinal scan; B: transverse scan

The images of each lesion were analyzed by an expert ultrasonographer. A tentative differential diagnosis was agreed upon, based on the following principles:

Cystic lesion: a anechoic well-contoured cavity surrounded by reinforced bone walls, filled with fluid and with no evidence of internal vascularization on color Doppler examination

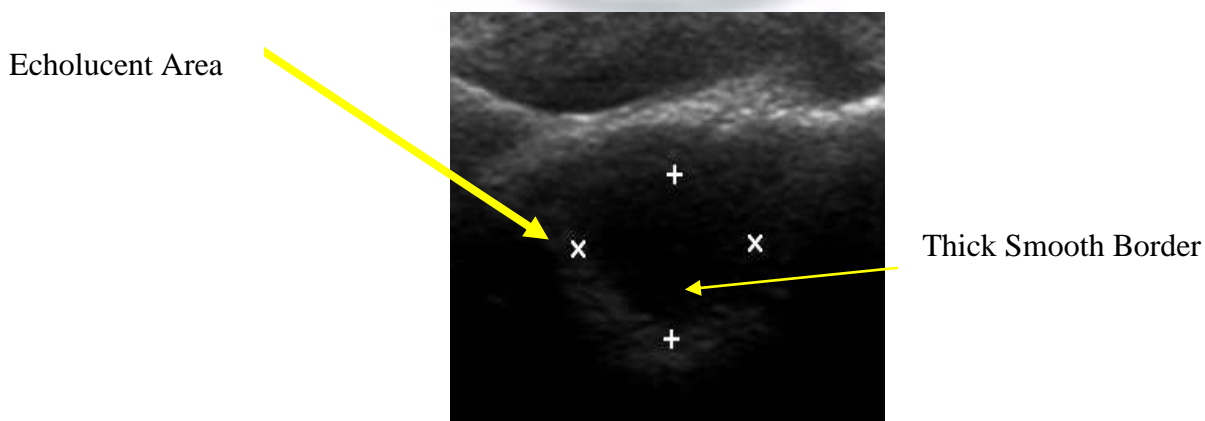
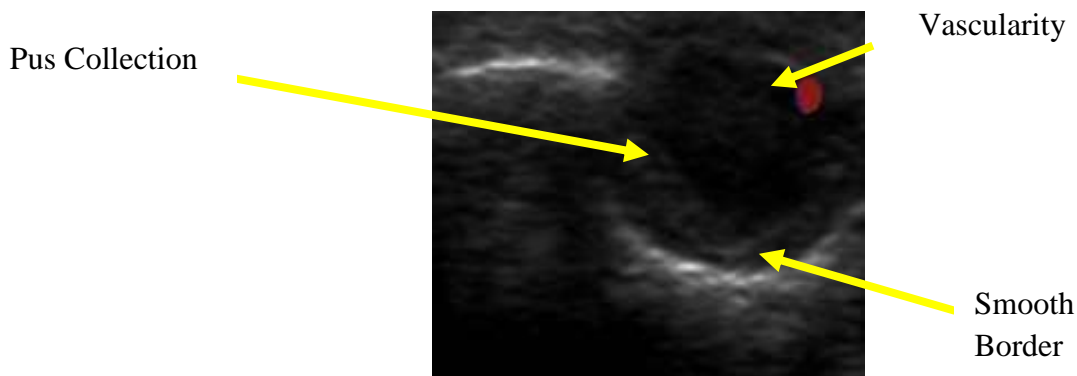


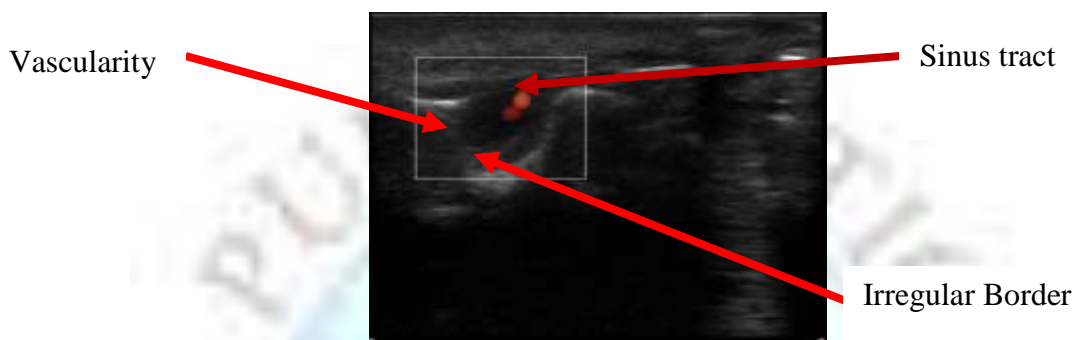
Figure (2): Demonstrated of radicular cyst

Periapical abscess predominantly hypoechoic area with focal anechoic area(heterogeneous echogenicity, light grayish), showing vascularity in some areas on color Doppler examination.



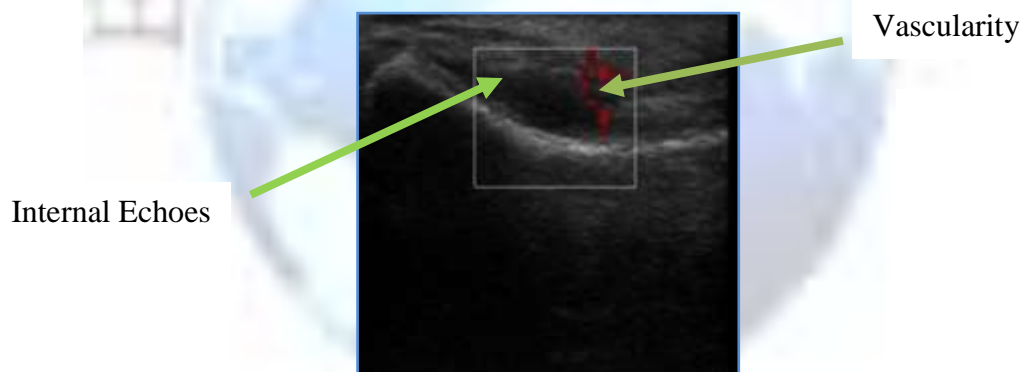
Figure(3): Ultrasound image of periapical abscess

Granuloma, a poorly defined hypoechoic area, showing rich vascular supply on color Doppler examination



Figure(4): Ultrasound images of periapical granuloma

Phoenix Abscess (Acute Exacerbation of Chronic Periapical Granuloma): Ill defined hypoechoic area with internal echoes and with rich internal vascularization on color Doppler ultrasound



Figure(5): Ultrasound image of phoenix abscess

Surgical Operation and Histopathological Examination

Surgical operation were made to all the patients and biopsies were obtained from the periapical areas. After fixation in 10% buffered formalin, the twenty surgical specimens were processed for routine histopathological examination.

RESULTS

Six cases show well defined anechoic area with reinforced bony walls and on color Doppler ultrasound shows no internal vascularization, these lesions diagnosed as radicular cyst.

Four cases show ill defined hypoechoic area with internal echoes and with internal vascularization on color Doppler ultrasound these lesion indicated granuloma with acute exacerbation (phoenix abscess).

One case shows ill defined hypoechoic area and with no vascularization on color Doppler ultrasound which is granuloma with fluid filled cavity inside.

Eight from 12 to 19 cases show ill defined hypoechoic area with vascularization on color Doppler ultrasound which indicated granuloma, one of these case show areas of extensive destruction of the architectural picture of the granulation tissue which is referred histologically as "ulceration."

In case twenty the echographist successfully described the lesion as periapical abscess with no vascularization on color Doppler ultrasound although histopathological report proved granuloma this may be due to blood collection following trauma just few hours before echographic examination or due to pus collection at acutely periapical lesions.

Five lesions show well defined hypoechoic area with focal anechoic area with evidence of bony wall echo structure of these lesion shows heterogeneous echogenicity(light grayish) and without or trace vascularization on color Doppler ultrasound this lesion describe as periapical abscess.

In the case sixty two the periapical lesion appears in a ultrasound as hypoechoic area with internal echoes which indicated as phoenix abscess, while histopathological report reveal as a granuloma this may be due to the date of operation and access opening is done for the patient to relive the pain of the patients and loss of abscess occurs before operationsurgery.

Histopathologic Reports

The results from the histopathological examination confirmed the echographic observations, in six lesions diagnosed as cystic lesions and showed the presence of a cavity lined with stratified squamous epithelium. Within the lumen of the cavity, necrotic debris and numerous impressions from cholesterol crystals were seen in two cysts while the other four cysts were with empty lumen which may be due to improper section preparation or loss of fluid during the histopathological reports on four lesions diagnosed as granuloma with acute exacerbations shows collection of granulation tissues with infiltrate of macrophage, netrophile and some of pus cell in addition to the tissue necrosis and derbies.

The histopathological reports of case number eleven with periapical cyst shows vascularization granulation tissues with infiltrate by netrophilis, macrophage with no evidence of stratified squemus epithelium lining.

The histopathologic reports on eight lesions consistently described a typical granulomatous appearance: connective tissue with widespread areas of polymorphs, lymphocytes, monocytes and newly formed blood vessels.

In five cases from 21 to 25 the morphological signs of a high level of inflammatory activity made it possible to establish the diagnosis “periapical abscess”. Histological sections revealed the central necrotic area consisting of clusters of aged, exposed, causing break down polymorphonuclear cells and vital leucocytes. The outer fibrous connective tissue with groups of proliferating endothelial cells was infiltrated by the cells of acute (neutrophils) and chronic (lymphocytes, macrophages, plasma cells) inflammation and cholesterol crystals.

Ultrasound result	Histopathological result	Case number
Radicular cyst	Radicular cyst	1
Radicular cyst	Radicular cyst	2
Radicular cyst	Radicular cyst	3
Radicular cyst	Radicular cyst	4
Radicular cyst	Radicular cyst	5
Radicular cyst	Radicular cyst	6
Phoenix abscess	Phoenix abscess	7
Phoenix abscess	Phoenix abscess	8
Phoenix abscess	Phoenix abscess	9
Phoenix abscess	Phoenix abscess	10
Granuloma	Granuloma with fluid filled cavity	11
Granuloma	Granuloma	12
Granuloma	Granuloma	13

Granuloma	Granulomas	14
Granuloma	Granuloma	15
Granuloma	Granuloma	16
Granuloma	Granuloma	17
Granuloma	Granuloma	18
Granuloma	Granuloma	19
Abscess	Granuloma	20
Abscess	Abscess	21
Abscess	Abscess	22
Abscess	Abscess	23
Abscess	Abscess	24
Abscess	Abscess	25
Phoenix abscess	Granuloma	26

Table(1): The result of ultrasound with histopathological examination

Groups	T P	T N	F P	F N	Sensitivity(%)	Specificity(%)	Accuracy(%)	PPV(%)	NPV(%)
Radicular cyst	6	1 9	0	1	85.71428571	100	96.15384615	100	95
Abscess	5	2 0	1	1	80	95.23809524	92.30769231	80	95.2380952
Granulo- ma	1 1	1 3	3	2	80	81.25	80.76923077	72.727273	86.6666667
Phoenix abscess	4	2 1	1	1	75	95.45454545	92.30769231	75	95.454545

DISCUSSION

Apical periodontitis is induced by prolonged exposure of periapical tissues to microbial agents derived from the infected root canal³⁰.

In the present study, the potential of ultrasound imaging and color Doppler ultrasound to describe the different content of periapical lesions and their vascularization was evaluated. The results obtained on twenty six lesions showed that there was a definite correlation between the echostructures of a lesion, its vascular supply and the nature of the lesion: cystic lesion, abscess, phoenix abscess and granuloma and this results agree with the result of Cotti et al.,2002; Cotti et al.,2003; Gundappa et al.,2006^{31; 27; 23}

Our study proved that ultrasound can give excellent result if there is bone perforation and this results are compatible with the results of Tikku et al.,2010,whom show that the use of ultrasound dose have some limitation , ultrasound with color Doppler cannot penetrate and thus confirm the presence of periapical lesion unless there is a breach or perforation in buccal bone plate³²

Lauria et al,1996, demonstrated that color and power Doppler ultrasound can provide information about the presence of blood flow within or around the examined tissue³³.This results consistent with may results. However, the presence of intact and thick vestibular cortical bone, the occurrence of infected cysts and solid areas within cystic lesions can cause pitfalls in the interpretation of ultrasonograms and this again consistent with our results.

Our study demonstrate that radicular cyst appear as anechoic area with no internal vascularization on color Doppler ultrasound only in some cases the radicular cyst appears as anechoic with internal echoes and with internal vascularization on color Doppler ultrasound and this explained as complicated cyst (cyst with inflammation) and this results harmonize with the results Lauria et al,1996; Sumer et al.,2009 and Chandak et al 2011^{33; 34; 35}. This unusual observation was explained with presence of a very thick periodontal capsule .

In the present study the results showed that the diagnosis of periapical granuloma were consistent with the biopsy report, and appears as ill defined hypoechoic area with internal vasculization on color Doppler ultrasound this results are similar to the result conduct by Sumer et al.,2009,who observed that twenty twolesions examined, the result showed that the diagnosis of periapical granuloma were consistent with the biopsy report³⁴.

In our study we conclude that the diagnosis of granuloma less precise because of small size of lesion and ill defined hypoechoic area and this result is in accordance with the results of Basrani, 2012, who concluded that the ultrasound diagnosis of periapical cyst is less precise and depends mostly on the type of the cyst and thickness of capsule³⁶.

Our study established that the diagnosis of cyst with the presence of a cavity partially or completely lined by epithelium; if the lesion was made up of granulation tissue with epithelial proliferation, but without cavitations, it was diagnosed as granuloma, the results are similar to the study conducted byNobuhara and Del Rio³⁷

In this study we indicated that the ultrasound images displayed lesions with solid content and a rich internal and external vascularity were described as infected granulomas or phoenix abscess which is granuloma with acute exacerbation and this results are harmonize with results of Cotti et al.,2003²⁷.

The diagnostic accuracy percentage for radicular cyst in relation to the histopathological result is 96% while the diagnostic accuracy percentage for abscess in relation to the histopathological result is 92% the accuracy percentage for granuloma in relation to the histopathological result is 80% this may be due that granuloma appears as ill defined hypoechoic lesion some time miss diagnosed as abscess or phoenix abscess, these findings were consistent with the studies of Cotti et al.,2002; Cotti et al.,2003 and Gundappa et al.,2006^{31; 27; 23}

CONCLUSION

Ultrasound real time imaging as a reliable diagnostic technique for differentiating periapical lesions, i.e. periapical cysts and granulomas, abscess and phoenix abscess based on the echotexture of their contents and the presence of vascularity using color Doppler in the anterior and posterior,upper and lower part of the mouth. Even sinus tracts and cystic lesions with complications, i.e. infected cyst can be detected.

REFERENCE

- [1]. Sabeti M , Kermani V, Sabeti S and James H. Simon J H.Significance of Human Cytomegalovirus and Epstein-Barr Virus in Inducing Cytokine Expression in Periapical Lesions. J Endod. 2012;38:47–50.
- [2]. Mirković S, Tadić A, Mirković TD and Levakov A.Comparative analysis of accuracy of diagnosis of chronic periapicalLesions made by clinical and histopatological examination. Med Pregl. 2012 ;7(8): 277-280.
- [3]. Peters E and Lau M .Histopathologic Examination to Confirm Diagnosis of Periapical Lesions: A Review. Can Dent Assoc. 2003; 69(9):598–600.
- [4]. Al-Kandari A M, Gnanasekhar D, Al-Quoud O A, Al-Anzi S A.Healing of a large periapical lesion in the palate following Non-surgical endodontic treatment. The Saudi Dental Journal. 1990; 2(2):62-65.
- [5]. Soares J, Santos S, Silveira F, Nunes E. Nonsurgical treatment of extensive cystlike periapical lesion of endodontic origin. Int Endod J.2006;39(7):566-75.
- [6]. Mukhaimer R, Hussein E, Orafi I.Prevalence of apical periodontitis and quality of root canal treatment in an adult Palestinian sub-population.The Saudi Dental Journal.2012 ;24, 149–155.
- [7]. Stashenko P, Teles R, D’Souza R. Periapical inflammatory responses and their modulation. Crit Rev Oral Biol Med. 1998;9: 498–521.
- [8]. Sağsen B, Şişman Y, ER Ö. Distribution of Root Filled Teeth and Apical Periodontitis in a Turkish Population from Cappadocia Region. Hacettepe Diş Hekimliği Fakültesi Dergisi. 2008;32(4):12-18
- [9]. Nair PN. On the causes of persistent apical periodontitis: a review. Int Endod J. 2006; 39(4): 249-281.
- [10]. Cawson RA and Odell EW. Cawson's Essential of Oral Pathology and Oral Medicine . Eight Edition, Churchill Livingston Elsevier; Edinburch London. 2008:Pp 67-69
- [11]. Ledesma-Montes C, Garcés-Ortiz M, Rosales-Garcia G, Hernandez-Guerrero J C.Importance of Mast Cells in Human Periapical Inflammatory Lesion. Journal of endodontics.2004; 30(12):855-859
- [12]. Ahmed GA, ElBaz A A, Hashem AAR, and Shalaan A K. Expression Levels of Matrix Metalloproteinase-9 and Gram-negative Bacteria in Symptomatic and Asymptomatic Periapical Lesions. J Endod. 2013;39:444–448
- [13]. Siqueira Jr J F and Rôças I N. Bacterial pathogenesis of apical periodontitis. Braz Dent J. 2007; 18(4): 267-280
- [14]. Noiri Y, i Ehara, Kawahara T, Takemura N and Ebisu Sh. Participation of Bacterial Biofilms in Refractory and Chronic Periapical Periodontitis. Journal of endodontics. 2002; 28(10):679-683
- [15]. Sabeti M, Valles Y, Nowzari H, Simon JH, Kermani-Arab V, Slots J.Cytomegalovirus and Epstein-Barr virus DNA transcription in endodontic symptomatic lesions. Oral Microbiol Immunol.2003;18:104-8.
- [16]. Hernadi K, Szalmas A, Mogyorosi R, et al. Prevalence and activity of Epstein-Barr virus and human cytomegalovirus in symptomatic and asymptomatic apical periodontitis lesions. J Endod. 2010;36:1485–9.
- [17]. Hernadi K, Csoma E, Adam B, et al. Association of human herpesvirus 6 subtypes with symptomatic apical periodontitis. Oral Surg Oral Med Oral Pathol Oral Radiol Endod. 2011;112:401–6.
- [18]. Li H, Chen V, Chen Y, et al. Herpesviruses in endodontic pathoses: association of Epstein-Barr virus with irreversible pulpitis and apical periodontitis. J Endod.2009;35:23–9.

- [19]. Saboia-Dantas CJ, de Toledo LFC, Sampaio-Filho HR, et al. Herpesviruses in asymptomatic apical periodontitis lesions: an immunohistochemical approach. *Oral Microbiol Immunol.* 2007;22:320–5.
- [20]. Sabeti M and Slots J. Herpesviral-bacterial coinfection in periapical pathosis. *J Endod.* 2004;30:69–72.
- [21]. Rammohan C. Ultrasound technology. In: Rammohan C. *Ultrasound unlimited. The A to Z ultrasound.* 1st edition. Hyderabad, India: Paras Medical Publisher.2005: Pp: 2–8.
- [22]. Palmer PES. Basics of ultrasound. In: Palmer PES. *Manual of diagnostic (New millennium edition).* AITBS. Publishers and Distributors (Regd). Delhi, India.2004: Pp: 3–5.
- [23]. Gundappa M, Ng SY, Whaites EJ. Comparison of ultrasound, digital and conventional radiography in differentiating periapical lesions. *Dentomaxillofac Radiol.* 2006; 35: 326–333.
- [24]. White SC and Pharoah MJ. *Oral Radiology: Principles and Interpretation.* Sixth Edition, Mosby St Louis; Canada.2009:Pp221-222.
- [25]. Gibbs V, Cole D and Sassano A. *Ultrasound , physics and technology.* First Edition . CHURCHILL LIV ELSEVIER. LONDON. 2009: Pp2-99 .
- [26]. Kaur K. Digital image processing in ultrasound images. *International Journal on Recent and Innovation Trends in Computing and Communication.* 2013;4(1): 388-393.
- [27]. Cotti E, Campisi G, Ambu R and Dettori C. Ultrasound real time imaging in differential diagnosis of periapical lesions. *Int Endod J.* 2003;36:556–63.
- [28]. Bagewadi S, Mahima VG, Karthikeya, Patil. Ultrasonography of swellings in orofacial region. *J Indian Acad Oral Med Radiol.* 2010;22(1):18–26.
- [29]. Sites BD, Brull R, Chan VWS , Spence BC, Gallagher J, Beach ML, Sites VR and Hartman GS (): Artifacts and Pitfall Errors Associated With Ultrasound-Guided Regional Anesthesia. Part I. Understanding the Basic Principles of Ultrasound Physics and Machine Operations. *Regional Anesthesia and Pain Medicine.*2007a; 32(5): 412–418.
- [30]. Hernadi K, Gyöngyösi E, Meszaros B, Szakacs L, Szalmas A, Eszter Csoma E, Mogyorosi R, Czompa L, Veress G, Varga I, Marton I J and Konya J. Elevated Tumor Necrosis Factor-alpha Expression in Periapical Lesions Infected by Epstein-Barr Virus. *J Endod.* 2013;39:456–460.
- [31]. Cotti E, Campisi G, Garau G, Puddu G. A new technique for the study of periapical bone lesions: ultrasound real time imaging. *Int Endod J.* 2002; 35:148-152.
- [32]. Tikku AP, Kumar S, Loombab K, Chandra A, Verma P and Aggarwal R. Use of ultrasound, color Doppler imaging and radiography to monitor periapical healing after endodontic surgery. *Journal of Oral Science.* 2010; 52(3):411-416
- [33]. Lauria L, Curi MM, Chammas MC, Pinto DS, Torloni H. Ultrasonography evaluation of bone lesions of the jaw. *Oral Surg Oral Med Oral Pathol Oral Radiol Endod.* 1996; 82: 351–357.
- [34]. Sumer AP, Danaci M, Sandikei EO, Sumer M and Celenk P. Ultrasonography and Doppler ultrasonography in the evaluation of intraosseous lesion in the jaws. *Dentomaxillofacial radiology.* 2009;38:23-27.
- [35]. Chandak, R, Degwekar S, Bhowte RR, Motwani M, Banode P, Chandak M and Rawlani S. An evaluation of efficacy of ultrasonography in the diagnosis of head and neck swellings. *Dentomaxillofacial Radiology.* 2011 ;40, 213–221.
- [36]. Basrain B. *Endodontic radiology.* 2^{ed} edition. Ch 19: Alternative imaging system in endodontic. WILEY-BLACKWELL, Inc. USA. 2012: Pp291-298.
- [37]. Nobuhara WK, Del Rio CE. Incidence of periradicular pathoses in endodontic treatment failures. *J Endod.*1993;19(6):315-8.