

Six anatomical landmarks for safe Laparoscopic Cholecystectomy

Rachit Arora¹, Bhavinder Arora²

¹VMMC and SJH, New Delhi

²MS, FIAMS, FAIS, Assoc. Professor, Department of Surgery, University of Health sciences, PGIMS, Rohtak

ABSTRACT

Background

Laparoscopic cholecystectomy is standard for treating cholelithiasis and assessing the laparoscopic surgical skills. Identification of extra hepatic anatomy is essential to avoid biliary, vascular and visceral injuries.

Material and methods

The study was conducted done in one hundred patients in which laparoscopic cholecystectomy done for cholelithiasis. Six basic anatomical landmarks were identified in all patients including thirty five patients of difficult cholecystectomy.

Results

Identification of gall bladder and cystic duct junction, also CBD and cystic duct junction is most reliable for avoiding biliary tree injuries. Entry point of cystic artery into gall bladder is the most reliable to avoid vascular injuries. There was no incidence of extra hepatic biliary or vascular injuries in our series.

Conclusion

A safe laparoscopic cholecystectomy for cholelithiasis is possible if these six basic anatomical landmarks are identified.

Key words

Anatomical landmarks, safe cholecystectomy, laparoscopic cholecystectomy, extra hepatic biliary anatomy.

INTRODUCTION

Laparoscopic cholecystectomy is accepted as the standard procedure for gall stone disease. Laparoscopic cholecystectomy is associated with more biliary, vascular and visceral complications when compared with open cholecystectomy. Different anatomy in laparoscopic view of the area around the gall bladder specially the Calot's triangle contributes to misidentification of structures.^{1,2} The limited magnified view of anatomy of Calot's triangle in laparoscopy is 2-dimensional vision as compared to 3-dimensional view in open cholecystectomy. The retraction of Hartmann's pouch during laparoscopic cholecystectomy tends to distort the Calot's triangle by actually flattening it rather than opening it out.³ A clear delineation of junction of the cystic duct with gall bladder is identified by cystic node of Lund with the demonstration of a space between the gall bladder and liver clear of any other structures other than cystic artery called the safety window or critical view has already been recommend as an essential step to prevent injury during laparoscopic cholecystectomy.^{4,5} After anterior dissection, the posterior dissection of the Calot's triangle, which is popular during laparoscopic cholecystectomy, again gives a different view of the area and since the gall bladder is flipped over during this method it may lead to further anatomical distortion.^{6,7} The Rouviere's sulcus is a fissure on the liver between right lobe and caudate process and is clearly visible during a laparoscopic cholecystectomy during posterior dissection in a majority of patients. Being an extra biliary reference point it does not get affected by distortion due to pathology.⁸

In view of the importance of anatomy of extra hepatic biliary system, it is logical to look at the possibility of assessing the anatomy while performing laparoscopic cholecystectomy. We describe six anatomical landmarks which must be identified during laparoscopic cholecystectomy to avoid injury to biliary ducts.

MATERIAL AND METHODS

This study was conducted on one hundred patients undergoing laparoscopic cholecystectomy for gall stone disease. The preoperative diagnosis was made in all the cases by ultrasonography. Standard four port laparoscopic cholecystectomy was done. In these patients neck first method was used, anterior dissection was followed by posterior dissection. Then dissection of Calot's triangle was done. In these patients, dissection of cystic duct and artery was carried. Hartman's pouch was identified and considering cystic duct of Lund as window is created near gall bladder neck. Cystic duct is identified and union of cystic duct with bile duct is identified, followed by applying the clips and division of cystic duct. Proceeding further with dissection cystic artery, it is identified and clipped near gall bladder. The rest of dissection is carried remaining near to gall bladder. The dissection proceeded on basis of six anatomical land marks.

1. Hartmann's pouch
2. Cystic node of Lund
3. Calot's triangle
4. Union of cystic duct with bile duct
5. Cystic artery and right hepatic artery
6. Rouviere's sulcus

RESULTS

Laparoscopic cholecystectomy was performed and depending on visualization of the anatomical landmarks, the laparoscopic cholecystectomy was labelled as simple or difficult. The anatomically simple laparoscopic cholecystectomy was done in 65 patients and difficult Laparoscopic cholecystectomy in 35 patients. These six basic anatomical land marks were identified in 65 patients and removal of gall bladder was uneventful, so labelled as simple. The difficult laparoscopic cholecystectomy includes:

1. Adhesion at Calot's triangle	15
2. Contracted and fibrotic gall bladder	5
3. Sleeve of fat over neck of gall bladder	10
4. Abnormalities of cystic duct union with bile duct	3
5. Abnormality of cystic artery	2

DISCUSSION

The Calot's triangle is bounded on the upper border by inferior surface of liver and on the other two sides by cystic duct and bile duct. Its contents usually include right hepatic artery, cystic artery, cystic lymph node of Lund, connective tissue and lymphatics.^{6,7} In reality it is a potential space rather than a large triangle making the dissection of its contents without damaging the bile duct, the most challenging step of laparoscopic cholecystectomy. In addition the space may be obscured and shrunk by inflammatory process and adhesion as a result of cholecystitis.^{4,5} The cystic duct joins the gall bladder to the bile duct and is an important structure which needs identification during laparoscopic cholecystectomy⁹. The cystic lymph node of Lund provides a guide to it¹⁰. The cystic duct may run a straight or a convoluted course and may be less than 2 cm in size in 20-year-old patients. The cystic duct is usually 2-3 mm wide but can dilate in presence of stones. The cystic duct joins the gall bladder at the neck and this angle is fairly acute. The mode of joining with gall bladder may be smooth tapering or abrupt. On the bile duct side its union may show significant variations. It is always safe to dissect the cystic duct with its junction to the bile duct. It is important to remember that even in low insertion variety of cystic duct it rarely goes behind the duodenum. So a duct behind the duodenum is more likely to be common bile duct. Therefore two ductal structures entering the gall bladder should always be viewed with suspicion⁶. The Hartmann's pouch is an out pouching of the wall in the region of the neck with pressure of stones. A large Hartmann's pouch may obscure cystic duct and Calot's triangle. This may result to its adherence to the bile duct. The small cystic duct can get completely hidden and traction on the gall bladder and can lead to bile duct looking like cystic duct. An exaggerated form of the same process is 'Mirizzi' syndrome in which a large stone in the Hartmann's pouch are either adherent to or erodes into the bile duct. This can create major difficulty during cholecystectomy². The cystic artery is a branch of right hepatic artery and is usually given off in the Calot's triangle. It has a variable length and enters the gall bladder in the neck or body area. It divides into anterior or superficial branch and posterior or deep branch. This branching usually takes place near the gall bladder. If the presence of the posterior branch is not appreciated it can cause troublesome bleeding during dissection. The right hepatic artery courses behind the bile duct and joins the right pedicle high-up in Calot's triangle. It may come very close to the gall bladder in form of Moynihan's hump. If such a hump is present cystic artery is very short. In this case right hepatic artery can be mistaken as cystic artery and can get torn¹¹. The Rouviere's sulcus is a fissure on the inferior surface of the liver between the right lobe and caudate process and is clearly seen during posterior dissection during laparoscopic cholecystectomy⁸.

CONCLUSION

Finally in this study it is concluded that identification of these landmarks is safeguard to biliary injuries. We agree that dissection of Calot's triangle is most important. The dissection should be kept as close to gall bladder as possible. While there has been a lot of focus on technology and technical skills, identification of anatomy and its relevance in prevention of biliary injuries needs space in future.

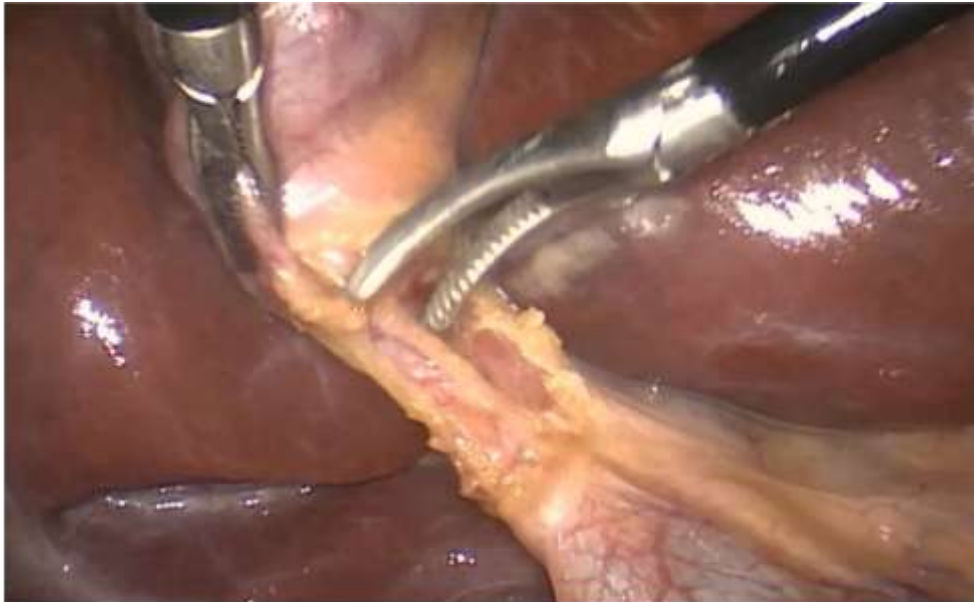


Fig 1. Anterior dissection showing junction of cystic duct with CBD

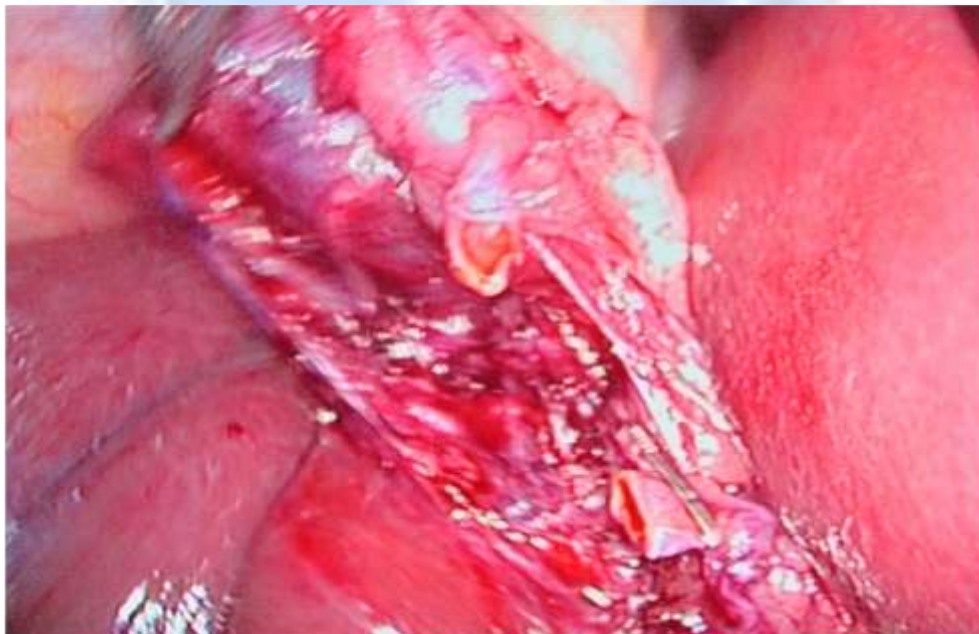

Fig 2. Showing posterior dissection

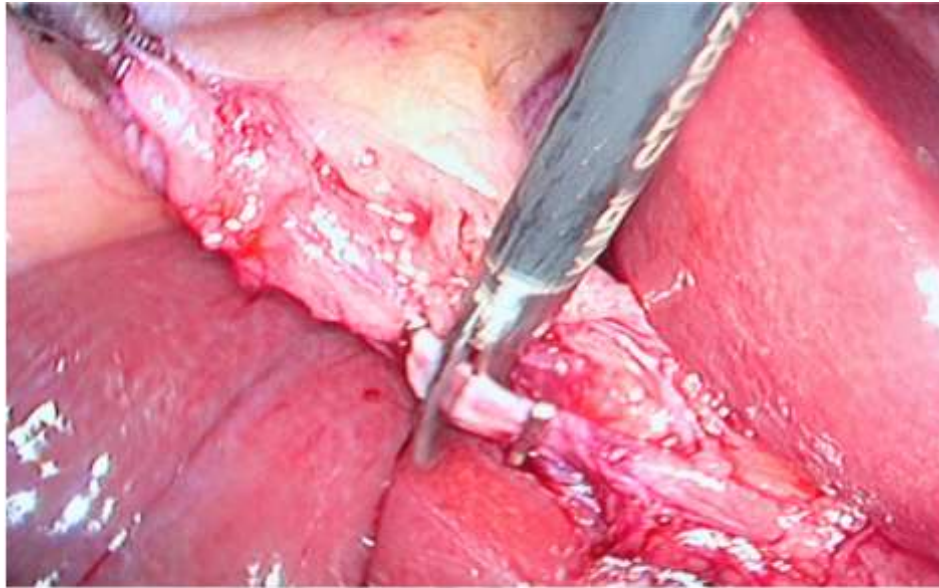


Fig 3. Cystic duct ligation

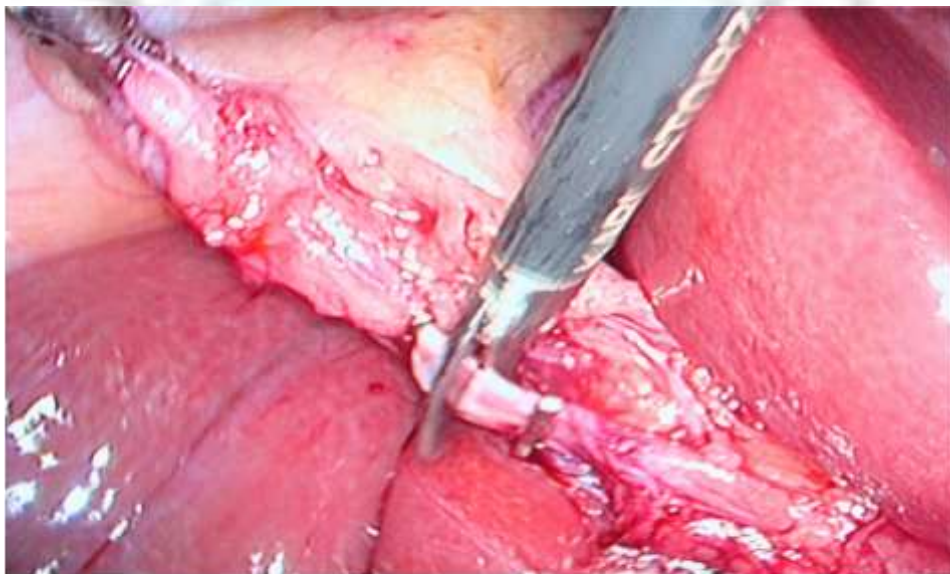

Fig 4. Cystic artery ligation

REFERENCES

- [1]. Singh K., Ohri L. Anatomical landmarks: their usefulness in safe laparoscopic cholecystectomy. *Surg Endosc* 2006; 20:1754-1758.
- [2]. Nagral S. Anatomy relevant to cholecystectomy. *J minim Access surg* 2005; 1(2):53-58.
- [3]. Crist D W, Gadaaz T R. Laparoscopic anatomy of the biliary tree. *Surg cilm North Am* 1993; 73(4): 785-98
- [4]. Hermann RE(1976). A plea for a safe technique of cholecystectomy. *Surgery* 79: 609-611.
- [5]. Yushi T, Henchi I, Ken K, Yukio Y, Masahiko O.(1993). Introduction of a 'safety zone' for the safety of laparoscopic cholecystectomy. *Am J Surg* 88:1258-1261.
- [6]. Desilva M, ferriando D. Anatomy of the calots triangle and its relevance to laparoscopic cholecystectomy. *Ceylon med J* 2001 mar;46(1):33-4.
- [7]. Rocko JM, Di Giora JM. Calots triangle revisited. *Surg gynecol obslet.*1981 sep; 153(3):410-4.

- [8]. Peti M, Moser MA. Graphic reminder of Rouviere's sulcus: a useful landmark in cholecystectomy. *AMZ j surg* 2012 may; 82(5):367-8.
- [9]. Katkhouda N, Mavor E, mason RJ. Visual identification of the cystic duct- CBD junction during laparoscopic cholecystectomy (visual cholangiography): an additional step for prevention of the CBD injuries. *Surg Endosc* 2000 jan;4(1):88-9.
- [10]. Kunasani R, Kohli H. Significance of the cystic node in preventing major bile duct injuries during laparoscopic cholecystectomy: a technique marker. *J laproendosc Adv surg Tech A*. 2003 oct 13(5):321-3.
- [11]. Hugh TB, Kelly MD, Li B. Laparoscopic anatomy of the cystic artery. *AmJSurg* 1992 jun;163(6):593-5.

