

Midline Diastema: Crossroad of Treatment Planning

Dr. Tanu Nangia¹, Dr. Gulsheen Kaur Kochhar², Dr. Sharda Yadav³,
Dr. Achla Bharti Yadav⁴, Dr. Vikas Setia⁵, Dr. Priyanka⁶

¹Assistant Professor, MPCDC, Gwalior, Madhya Pradesh, India

²Assistant Professor, Swami Devidayal Hospital & Dental College, Barwala, Panchkula, Haryana, India

³Senior Resident, Dr. RML Hospital, Delhi, India

⁴Senior Lecturer, Department of Oral Pathology, Mithila Minority Dental College & Hospital, Darbhanga, Bihar, India

⁵Assistant professor Department of Pedodontics & Preventive Dentistry Adesh Institute of Dental Sciences and Research Bathinda, Punjab, India

⁶Senior Lecturer, Department of Pedodontics, MM College of Dental Sciences & Research, Mullana, Ambala, Haryana, India

Abstract: Space or gap existing in the midline of the dental arch is termed as Midline Diastema. Maxillary midline diastemas are a common esthetic problem. The importance of the presence of a maxillary midline diastema resides in its position and the concern it causes to patients. The need for treatment is mainly attributed to esthetic and psychological reasons, rather than functional ones. It is important to understand the cause of the particular condition in order to undertake its proper treatment. This paper reviews different treatment techniques to manage the situation and presents two cases with midline diastema.

Keywords: midline diastema, esthetic, spacing, mesiodens, frenectomy, composite restoration.

Introduction

A diastema is defined as a space greater than 0.5mm between the proximal surfaces of adjacent teeth¹. Angle (1907) described the dental midline diastema as rather common form of incomplete occlusion characterized by a space between the maxillary and less frequent– mandibular central incisor^{2,3}. The space can be a normal physiologic characteristic during the primary and mixed dentition and generally is closed by the time the maxillary canines erupt. For most children, the medial erupting path of the maxillary lateral incisors and maxillary canines, as described by Broadbent, results in normal closure of this space^{3,4}. For some individuals, however, the diastema does not close spontaneously. We report two different cases of midline diastema.

Case Reports

A 19 year old male reported with the chief complaint of spacing in the upper front tooth region. The patient was unhappy with the appearance of his teeth and restrained himself from smiling due to self-consciousness. The patient's medical history did not reveal any systemic diseases. Intra-oral examination revealed midline spacing between maxillary central incisors. The spacing ranged from 1-1.5mm, so it was decided to use composite resin to close the diastema conservatively. Composite resin build up was done to close the Diastema. There was a remarkable improvement in the aesthetics, due to spontaneous closure of midline Diastema. (Fig1 &2)

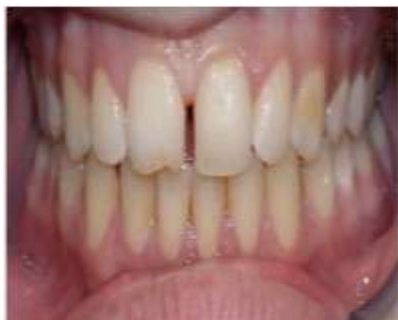

Fig 1

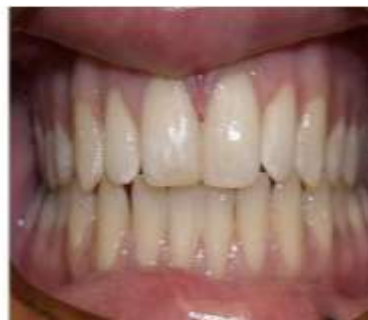

Fig 2

Another patient 17yrs. Male reported to our clinic with chief complaint of spacing in the upper front tooth region. The patient's midline history did not reveal any systemic diseases. Intra-oral examination revealed presence of high frenal attachment and midline spacing between maxillary central incisors (3mm). A Simple diagnostic test, i.e. blanching test was performed for an abnormal high frenum by observing the location of the alveolar attachment when intermittent pressure was exerted on the frenum. After obtaining informed consent decision was made to remove high frenal attachment by a surgical technique.

Frenectomy was carried out under local anaesthesia with incision using No.15 Bard parker blade. In this technique, lateral incisions were made on either side of the frenum to the depth of the underlying bone. The wedge of tissue was picked up with tissue forceps and excised with tissue shears at the area close enough to the origin of the frenum to provide a desirable cosmetic effect. Sutures were placed and periodontal pack was placed. The patient was advised to return after a week for suture removal. The diastema was then closed orthodontically. (fig 3,4 &5).

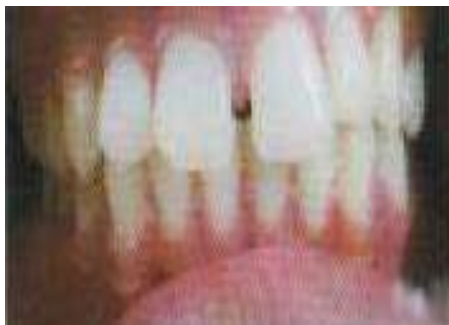

Fig 3

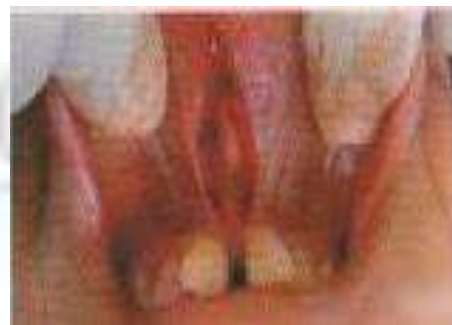

Fig 4

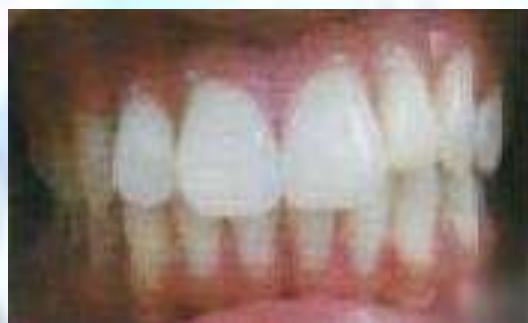

Fig 5

Discussion

Midline diastema always “creates an unpleasant appearance and interferes with speech depending on its width” {Angle1907}². It is important to understand the cause of the particular condition in order to undertake its proper treatment. Broadbent (1941) described the maxillary midline diastema in growing children as non-esthetically pleasing and characterized it as the “ugly duckling” stage of dental development⁴. He considered this stage as a transitional phase for the maxillary interincisal diastema, indicating the space available for the erupting permanent dentition. Broadbent also described the closure of this diastema with complete eruption of lateral incisors and canines as a normal stage of occlusal development⁴. In adult dentition reported incidence ranges from 5% to 20%⁵. Suggested causes include missing or undersized lateral incisors; mesiodens; Para functional habits such as thumb sucking, mouth breathing and tongue thrusting, flared or rotated incisors, anodontia; macroglossia; dentoalveolar disproportion; localized spacing; closed bite; ethnic and familial characteristic and midline pathology⁶.

Multiple factors may contribute for midline diastema including oral habits, soft tissue imbalances, dental anomalies and/or dental/skeletal disharmonies, as well as normal Dentoalveolar development as proposed by Becker Edwards, Steigman, Clark, Bishara, and Campbell⁷⁻¹⁰.

1. Genetic nature of Midline Diastema

Gass et al. (2003) observed that preliminary results from thirty families show a possible genetic basis for Diastema. More specifically, “heritability” was estimated at 0.32 for the white and 0.04 for the black population “Heritability” is defined as the ratio of the total genotypic diversity to the total phenotypic diversity with values ranging from 0 to 1¹¹. Data from family trees suggest a dominant autosomal hereditary type. Schmitt (1982) described eight members of a family who, for more than three generation, presented a syndrome including bilateral triphalangeal thumbs, radial hypoplasia, hypospadias (congenital abnormality of the urethra) and Maxillary Diastema. All family members with the disease had a Midline Diastema¹².

2. Environmental nature of Midline Diastema

- Hypertrophic labial frenum.
- Peg laterals.
- Congenital tooth absence.
- Presence of supernumerary tooth (Mesiodens).
- Displaced teeth in maxillary anterior segment.
- Odontomas.
- Excessive anterior overbite.
- Dento-alveolar trauma

3. Oral Habits:

- Finger sucking/Tongue thrust.
- Tongue movement or size may result in interincisal spacing.

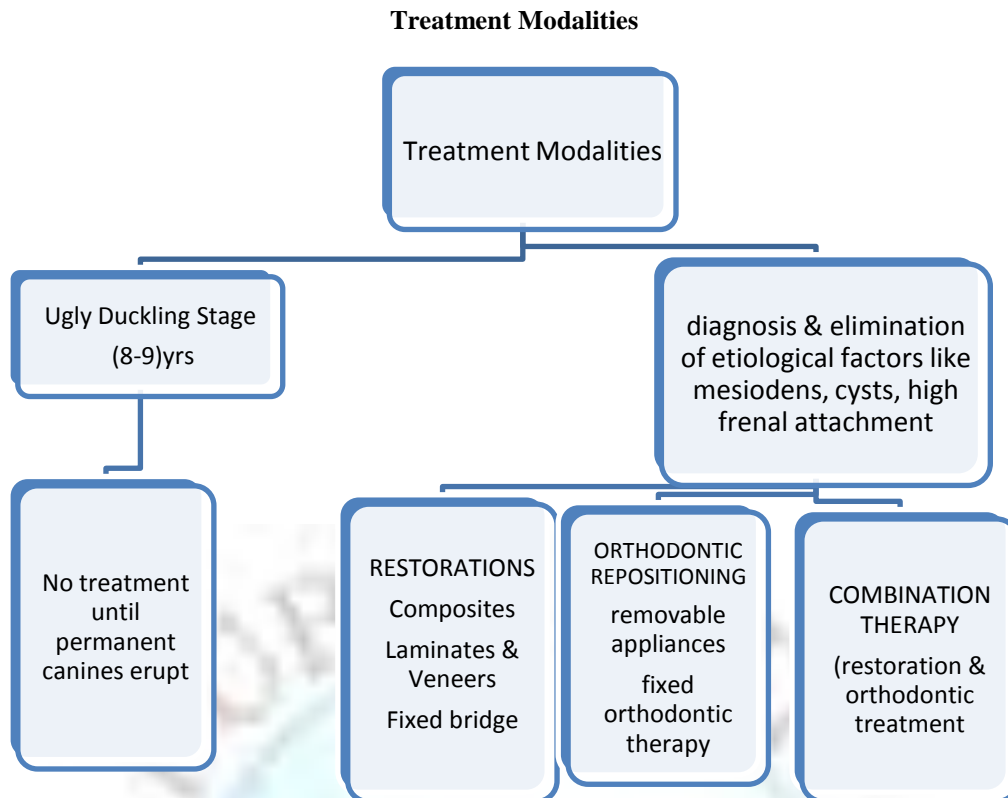
4. Pathological:

- Excessive interdental caries.
- Periodontitis.
- Cysts and tumours.

Before determining the optimal treatment, one must consider the contributing factors. These include normal growth and development, tooth size discrepancies, excessive incisor vertical overlap of different causes, mesiodistal and labio-lingual incisor angulation, generalized spacing and pathological conditions¹³. Maxillary midline diastemas are a part of normal development in children. In growing patients, midline diastemas often appear during a transitory stage of development, and then close spontaneously. The great majority of diastemas closes after the eruption of the maxillary canine teeth and requires no intervention by the dentist.

Diastemas larger than 2 mm and diastemas in patients with generalized spacing are at risk of not closing with normal development¹⁰. In adults, tooth-size discrepancies and excessive vertical overlap of the incisors are the most common factors in the development of midline diastema. Many treatment modalities have been used, varying from restorative procedures to surgery (frenectomies) and orthodontics¹⁴. A carefully developed diagnosis and advanced planning allows the most appropriate treatment to be determined for each individual case to address the patient's needs¹⁵. Diastemas based on tooth-size discrepancy are most amenable to restorative and prosthetic solutions. The most appropriate treatment often requires orthodontically closing the midline diastema⁶.

Occasionally a local cause must be identified and eliminated before the diastema can be closed orthodontically with a stable result. The ideal treatment should seek to manage not only the diastema in question but also the cause behind it. Aesthetic rehabilitation for closure of diastemas is guided by the principles of proportion. The width to length ratio of the centrals must follow the principles of golden proportion¹. Direct bonding in diastema closure cases allows the dentist and the patient complete control in the formation of that smile⁶.



Conclusion

Maxillary midline diastemas are a common esthetic problem that dentists must treat. The need of the treatment is mainly attributed esthetic & psychological reasons, rather than functional. A thorough diagnosis should be made, taking into consideration the etiological factors involved. Treatment planning should be made accordingly, varying from restorative procedures to surgery (frenectomies) and orthodontics.

References

- [1]. Nainar S M; Gnanasundaram N. Incidence and etiology of midline diastema in a population in south India (Madras), Angle orthod, 1989;59(4):277-82.
- [2]. Angle EH. Treatment of malocclusion of the teeth, 7 edition. Philadelphia: S.S. White Dental Manufacturing co., 1907;63:209-12.
- [3]. Alexandros T, Moullas. Maxillary midline diastema: a contemporary review. Hellenic orthodontic review 2005, volume 8, issue 2.
- [4]. Broadbent BH. Ontogenic development of occlusion. Angle Orthod, 1941;11:223-241
- [5]. Shashua D, Artun J, Odont, Relapse after orthodontic correction of maxillary median diastema: A follow up evaluation of consecutive cases, AngleOrthodontics,1999;69(3):257-63.
- [6]. Bhattacharya P, Raju P S, Bajpai A. Prognosis v/s etiology: midline papilla reconstruction after closure of median diastema. Annals and Essences of Dentistry, 2011; 3(1)
- [7]. Wen-Jeng uang, Huang, DDS Curtis J. Creath, DMD, MS. The midline diastema: a review of its etiology and treatment. American Academy of Pediatric Dentistry1995;17:3
- [8]. Becker A. The median diastema. Dental clinics of North America. 1978;22(4):685-710
- [9]. Bishara SE. Management of diastema in Orthodontics. American J of Orthod.1972;61:55-63
- [10].) Edwards JG. The diastema, the frenum, the frenectomy: a clinical study. Am J Orthod 1977;71(5):489-507.
- [11]. Gass JR, Valiathan M, Tiwari HK, Hans MG, Elston RC. Familial correlations & heritability of maxillary midline diastema. Am J Orthod Dentofacial orthop 2003;123:35-9
- [12]. Schmitt E, Gillenwater JY, Kelly TE. An autosomal dominant syndrome of radial hypoplasia, triphalangeal thumbs, hypospadias & maxillary diastema: Am J Med Genet 1982;13:63-9
- [13]. Chu FC, Siu AS, Newsome PR, Wei SH. Management of median diastema. Gen Dent. 2001;49(3):282-7.
- [14]. Oesterle LJ, Shellhart WC. Maxillary midline diastemas: a look at the causes. Am Dent Assoc. 1999 Jan; 130(1):85-94.
- [15]. Oquendo A, Brea L, David S. Diastema: correction of excessive spaces in the esthetic zone. Dent Clin North Am. 2011 Apr;55(2):265-81.