

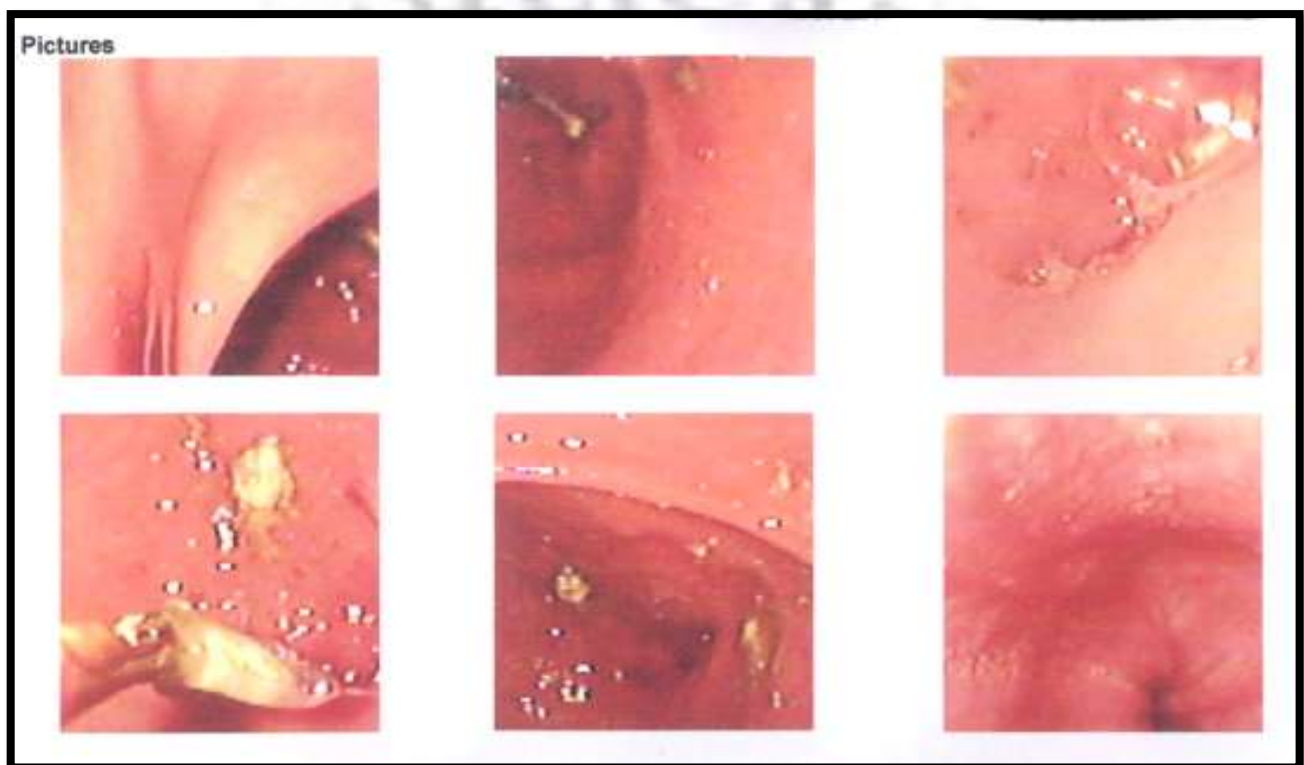
Acute gastric outlet obstruction with PPI tablet

Dr. Bhavinder Arora¹, Dr. Hans Raj Ranga²

^{1,2}Associate Professor, Department of Surgery, Pt. BDS University of Health Sciences, PGIMS, ROHTAK- 124001

CASE SUMMARY

A 52 years female presented with pain in epigastrium and vomiting. The pain was of one day duration only. The treatment history included injection for pain and a ppi tablet. The patient continued with relentless pain and vomiting. As the patient was not relieved, the upper G I endoscopy revealed a tablet obstructing the gastric outlet, which was removed. The epigastric pain and vomiting ceased immediately and patient recovered well.



PRESENTA

1. WALL OF PYLORIC PART OF STOMACH
2. TABLET SEEN IN PYLORUS
3. TABLET SEEN IN PYLORUS
4. TABLET BROKEN
5. TABLET BROKEN
6. PYLORUS VIEW SHOWING TABLET REMOVED

DEFINITION

Gastric outlet obstruction also known as pyloric obstruction is not a single entity. It is a clinical and pathophysiological consequence of any disease process that produces a mechanical impediment to gastric emptying. Gastric outlet obstruction is described as mechanical obstruction in pylorus or antrum.^{1,2,3,4,5}

CLASSIFICATION

A. BENIGN

1. INTRALUMINAL

- .HETROTOPIC PANCREAS
- .GALL STONE
- .RECURRENT JEJUNODUODENAL OBSTRUCTION
- .BEZOARS
- .FRUIT SEEDS LIKE MANGO
- .ENTERIC COATED TABLET

2. INTRAMURAL

- .PEPTIC ULCERATION
- .CAUSTIC INGESTION
- .EOSINOPHILIC GASTROENTERITIS
- .TUBERCULOSIS
- .AMYLOIDOSIS
- .DIABETIC GASTROPARESIS

3. EXTRAMURAL

- .PANCREATIC PSEUDOCYSTIC

B. MALIGNANT

- .LYMPHOMA
- .GASTROINTESTINAL STOMAL TUMOUR
- .ADENOCARCINOMA

Many of these causes are uncommon. Acute gastric outlet obstruction by a ppi tablet is rare, ppi tablet are frequently used in treatment of peptic disease.

PATHOPHYSIOLOGY

The ppi tablet is frequently used as a part of peptic disease treatment. The ppi tablets are small in size and are enteric coated.

A tablet can cause obstruction only in certain pre conditions.

- Due to peptic ulcer disease there was pylorospasm due to which this small size tablet could not pass through it.
- The coating over the tablet was definitely defective as it did not dissolve after 12 hours.
- There was no pyloric stenosis.
- The tablet was definitely obstructing the lumen of pylorus, as with multiple vomiting the ppi tablet could not come out. Only snare was able to break the tablet.

DISCUSSION

Tablet obstruction due to defective film coating and peptic ulceration is a well known entity in patient using non steroidal anti-inflammatory drugs like ibuprofen. The ulceration is common in these patients. We are unable to search any such case in literature

CONCLUSION

Acute gastric outlet obstruction by ppi tablet in a patient with pain abdomen is rare entity of clinical interest. This can be easily treated with endoscopic removal of tablet.

References

- [1]. Chowdhury A, Dhali GK, Banerjee PK. Etiology of gastric outlet obstruction. Am J Gastroenterol 1996;91:1679
- [2]. Kreel L, Ellis H. Pyloric stenosis in adults: A clinical and radiological study of 100 consecutive patients. Gut 1965; 6:253.
- [3]. Johnson CD, Ellis H. Gastric outlet obstruction now predicts malignancy. Br J Surg 1990; 77:1023.
- [4]. Samad A, Khanzada TW, Shoukat I. Gastric Outlet Obstruction: Change in Etiology. Pakistan Journal of Surgery 2007; 23:29.
- [5]. Goldstein H, Boyle JD. The saline load test--a bedside evaluation of gastric retention. Gastroenterology 1965; 49:375.
- [6]. DiSario JA, Fennerty MB, Tietze CC, et al. Endoscopic balloon dilation for ulcer-induced gastric outlet obstruction. Am J Gastroenterol 1994; 89:868.
- [7]. Gencosmanoglu R, Sen-Oran E, Kurtkaya-Yapicier O, Tozun N. Antral hyperplastic polyp causing intermittent gastric outlet obstruction: case report. BMC Gastroenterol 2003; 3:16.
- [8]. Bakken DA, Abramo TJ. Gastric lactobezoar: a rare cause of gastric outlet obstruction. Pediatr Emerg Care 1997; 13:264.

