

Histopathological and Immunological Assessment of the effect of Topical Application of Curcumin in Orabase Paste on the Healing of Oral Mucosal and Cutaneous Wounds

Ali Idrees¹, Hafidh Ibraheem Al-Sadi²

¹BDS, MSc., Department of Oral and Maxillofacial Surgery, College of Dentistry, University of Mosul, Iraq.

²BVMS, MS, PhD. Department of Oral and Maxillofacial Surgery, College of Dentistry, University of Mosul, Iraq.

ABSTRACT

Aims: Histopathological and immunological studies were carried out to demonstrate the effectiveness of topical application of curcumin on the healing of cutaneous and oral mucosal wounds.

Materials and Methods: Fifty apparently healthy adult male rabbits of mixed breed were used. A standard round 0.8 cm diameter full-thickness skin wound and a second identical oral mucosal wound were aseptically induced in each rabbit using a locally made device. The animals were then divided into two equal groups: control (no treatment), curcumin (treatment with curcumin and orabase). The treatment protocol for material was once daily for 3 continuous days. Biopsies were collected from the oral and skin wounds for 5 rabbits from each group at 1, 3, 7, 15 and 30 days, and processed histopathologically. Blood samples were collected from all rabbits and were used for measurements of the serum level of IL-6 and TNF- α using ELISA Kits.

Results: Histopathological and statistical findings of this study indicated that inflammation and re-epithelialization was more pronounced in curcumin treated skin and oral mucosal wounds than control skin and oral mucosal wounds. Significant differences ($P < 0.05$) were found in concentration of IL-6 and TNF- α in sera of control and curcumin treated groups.

Conclusions: Curcumin has significant effects on the healing of full thickness secondary cutaneous and oral mucosal wounds. There was significant fluctuation in the serum concentration of IL-6 and TNF- α in both the control and the curcumin treated rabbits for the 1,3,7,15 and 30-day periods.

Key words: Curcuma Longa, Oral Soft Tissue Wound Healing, Cutaneous Wound Healing.

HOW TO CITE THIS ARTICLE

Ali Idrees, Hafidh Ibraheem Al-Sadi, "Histopathological and Immunological Assessment of the effect of Topical Application of Curcumin in Orabase Paste on the Healing of Oral Mucosal and Cutaneous Wounds", International Journal of Enhanced Research in Science, Technology & Engineering, ISSN: 2319-7463, Vol. 7 Issue 2, February-2018.

INTRODUCTION

Curcumin [(1E,6E) -1,7-bis (4-hydroxy-3-methoxyphenyl) hepta-1,6-diene-3,5-dione] is the major natural yellow pigment in turmeric isolated from the rhizome of the plant *Curcuma longa*. Curcumin has been found to inhibit the generation of ROS including superoxide and hydrogen peroxide in peritoneal macrophages ^[1]. It also inhibits lipopolysaccharide and interferon- γ -induced production of nitric oxide in macrophages ^[2] and inducible nitric oxide synthase gene expression in isolated BALB/c mouse peritoneal macrophages ^[3]. As anti-inflammatory agent, curcumin inhibits the proliferation of several tumor cells ^[4]. Curcumin has been reported to have anti-clastogenic ^[5], anti-fungal ^[6] and anti-viral properties ^[7].

In vitro studies have shown significant activity of the essential oil of *Curcuma zedoaria* against Gram- positive and – negative microorganisms and fungi^[8] as well as low toxicity when fluid extract is used in preparation for oral hygiene, mostly for antiseptic purposes^[9]. Papiez (2013)^[10] found that curcumin significantly attenuated etoposide-induced oxidative DNA damage. Curcumin also significantly reduced the DNA strand break and hypoplasia caused by cytostatic drug. Curcumin induce anti-apoptotic function by the regulation of heme oxygenase-1 (HO-1) protein through the PI3K1/Akt signaling pathway. Curcumin might be used as a preventive and therapeutic agent for treatment of cardiovascular diseases associated with oxidative stress^[11].

Several studies have suggested the beneficial effects of curcumin as a wound-healing agent^[12,13,14,15,16,17]. Bhagavathula *et al.* (2009)^[18] showed that topical pre-treatment with a combination of curcumin and ginger extract improved healing of subsequently-induced abrasion skin wounds in corticosteroid –treated rats. Jagetia and Rajanikant (2004)^[19] studied the effect of curcumin on radiation-impaired healing of excisional wounds in mice. They found that treatment with curcumin resulted in a dose- dependent increase in contraction when compared with a control. Greatest contraction was observed for 100mg/kg curcumin, with statistically significant results at days three ($P < 0.009$), six ($P < 0.05$) and nine ($P < 0.05$) post-irradiation for this dose. Complete healing was achieved by day 23 post-irradiation in the curcumin–treated irradiation group.

Kulac *et al.* (2013)^[20] studied the effect of topically administered curcumin on burn wound healing in rats. They found that curcumin caused a significant increase in the hydroxyproline levels in the skin and the curcumin treated burn wounds healed much faster as indicated by improved rates of inflammatory cells, collagen deposition, angiogenesis, granulation tissue formation and epithelialization. There was a rise in the expression of proliferating cell nuclear antigen in skin tissues. These authors concluded that topical application of curcumin has beneficial effects in the acceleration of wound healing.

Cherreddy *et al.* (2013)^[21] studied the effect of poly (lactic-co-glycolic acid) (PLGA) nanoparticles encapsulating curcumin on the healing of full-thickness excisional wound healing mouse model. They found that PLGA-curcumin nanoparticles showed a twofold higher wound healing activity compared to that of PLGA or curcumin. Histology and RT-PCR studies confirmed that PLGA –curcumin nanoparticles exhibited higher re-epithelialization, granulation tissue formation, and anti-inflammatory potential. Akbik *et al.* (2014)^[22] reviewed the literature on the effects of curcumin on wound healing. They provided evidence for the ability of curcumin to enhance collagen deposition, granulation tissue formation, tissue remodeling and wound contraction.

MATERIALS AND METHODS

Fifty apparently healthy adult male rabbits (of mixed breed) were used in this study. The animals were bought from a local vendor and their average weight was 1.5 ± 0.5 kg. The rabbits were kept in an animal house with constant temperature of 24°C , good ventilation, 12 hours light-dark cycle, and were given food (vegetable, grain and corn) and water ad libitum (as desired). Curcumin used in this study was bought as a crude product from a local market in Mosul city and its isolated from the rhizome of the plant *Curcuma longa*. Concentration of curcumin of 10g/100ml^[18] of orabase paste according to the procedure described by Al-Nema (2000)^[23] was used in this study. The rabbits were randomly divided into 2 equal groups of 25 rabbits, each rabbit was anesthetized using 40mg/kg. Ketamin injection^[24] intramuscularly in the thigh muscle, mixed with xylazine 4mg/kg^[25] following induction of anesthesia, a standard round 0.8 cm full thickness skin defect was induced by using punch biopsy (locally made device). Identical defect is induced in the oral mucosa of the right cheek.

The treatment protocol for the treatment group was done once daily for three continuous days. Biopsies were collected from the oral and skin defects of five rabbits from each of the groups at 1,3,7,15 and 30 days. Both skin and oral biopsies were preserved in freshly prepared 10% formalin for 48 hours. Blood sample for measurements of IL-6 and TNF- α were collected from the rabbits at the same intervals as indicated above. Following fixation of tissue specimens, they were stained with hematoxylin and eosin (H&E) stain and examined under light microscope to evaluate the inflammatory response and re-epithelialization depending on the score described by Camacho-Alonso *et al.*, 2005; Camacho-Alonso *et al.*, 2008; Lopez-Jornet *et al.*, 2009 and Albanna, 2010^[26,27,28,29].

The concentration of TNF- α in serum was measured using TNF- α ELISA kit provided by MyBiosource.com. and IL-6 serum concentration was determined using the IL-6 ELISA kit provided by MyBiosource.com.

Statistical analyses

Analysis of the results was done using SPSS 19 computer software program. Mann–Whitney NPar Test was used to compare between means of various groups. Statistical significance was accepted for P -value ≤ 0.05 . Furthermore, results of estimations of serum concentration of IL-6 and TNF- α in various groups and during the various post-wounding days were analyzed using the one-way analysis of variance at $P \leq 0.05$.

RESULTS

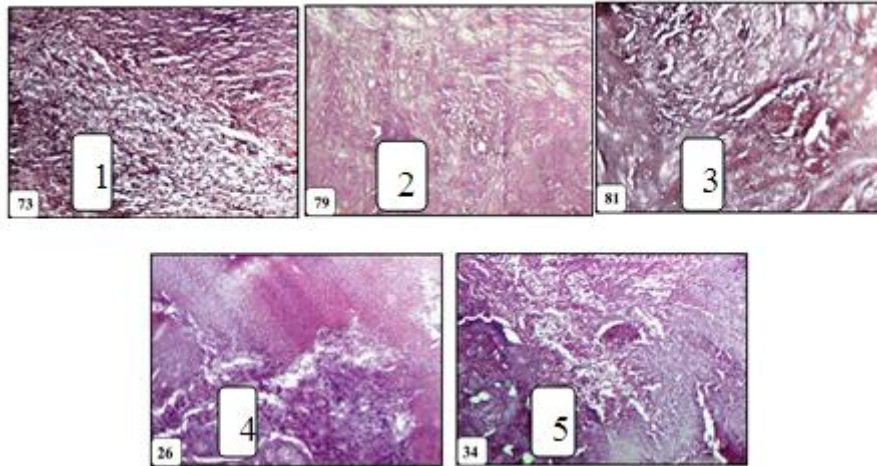


Fig. (1): A view of the dermal part of a 15-days skin wound treated with curcumin. Fibrous tissue has filled the dermal wound and there is only scarce number of inflammatory mononuclear cells. H&E. X100.

Fig. (2): A 15-days oral mucosal wound treated with curcumin. Dense fibrous tissue is evident in the submucosal wound. H&E. X100.

Fig. (3): The submucosal part of a 30- days oral mucosal wound treated with curcumin. Note the presence of mature fibrous tissue in the wound. H&E. X100.

Fig.(4): A view of a 7-days skin wound in a control rabbit. A marked thickness of the epidermis adjacent to the wound is evident. Granulation tissue consisting of fibroblasts, collagen fibers, and blood capillaries is visible in the dermal wound, H &E, X100.

Fig. (5): A view of 3-days oral mucosal wound in a control rabbit. A large quantity of granulation tissue is evident in the submucosal wound. H &E,X100.

The mean scores of inflammation and re-epithelialization for the whole rabbits of control and curcumin treated groups and for all time periods 1,3,7,15 and 30 days all are shown in (Table 1 and 2).

Table(1) :Mean values of scores of inflammation and re-epithelialization of skin and oral mucosal wounds in control group

Days	Skin		Mucosa	
	Inflammation	Re-epithelialization	Inflammation	Re-epithelialization
1	0.52	0.0	0.34	0.36
3	1.8	0.53	1.8	2.95
7	3.25	2.15	3.85	3.65
15	3.30	2.70	3.65	4.00
30	3.75	3.75	3.85	3.90

Table(2): Mean values of scores of inflammation and re-epithelialization of skin and oral mucosal wounds in curcumin treated group

Days	Skin		Mucosa	
	Inflammation	Re-epithelialization	Inflammation	Re-epithelialization
1	0.46	0.00	0.70	0.55
3	2.00	0.85	3.5	3.2
7	3.15	1.45	3.1	3.1
15	3.95	4.00	4.00	3.55
30	3.8	4.05	4.00	4.00

Inflammation was significantly higher ($P < 0.05$) in curcumin treated skin wounds than in control wounds during the 15-day period (Table 3 and Fig.6). Re-epithelialization was significantly higher ($P < 0.05$) in curcumin treated skin wounds than in control skin wounds for the 7 and 15-day periods (Table 3 and Fig.7).

Results of the Mann-Whitney test for the oral mucosal wounds in the control and curcumin treated groups are presented in (Table 4). Inflammation was significantly higher ($P < 0.05$) in mucosal curcumin-treated mucosal wounds than in control mucosal wounds for the 1, 3, and 15-day periods (Table 4 and Fig 8.). Re-epithelialization was significantly higher ($P < 0.05$) in curcumin-treated mucosal wounds than in control mucosal wounds for the 7-day period (Table 4 and Fig.9).

Table (3): Mann-Whitney test comparing between inflammation and re-epithelialization in control and curcumin treated skin wounds.

Duration	Inflammation (p-value)	Re-epithelialization
Day 1	0.655	0.955
Day 3	0.228	0.084
Day 7	0.669	0.026 (*)
Day 15	0.008 (*)	0.008 (*)
Day 30	0.654	0.082

Significance (*), P value ≤ 0.05 .

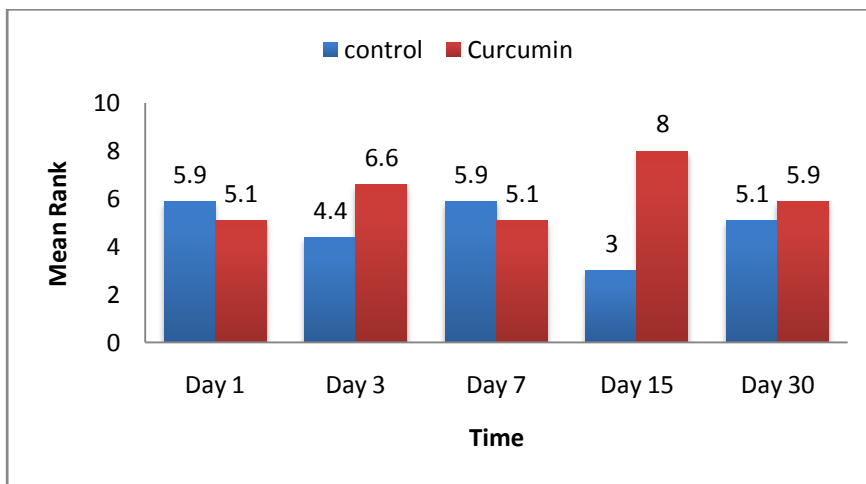


Fig. (6): Mann-Whitney mean ranks for inflammation in control and curcumin treated skin wounds.

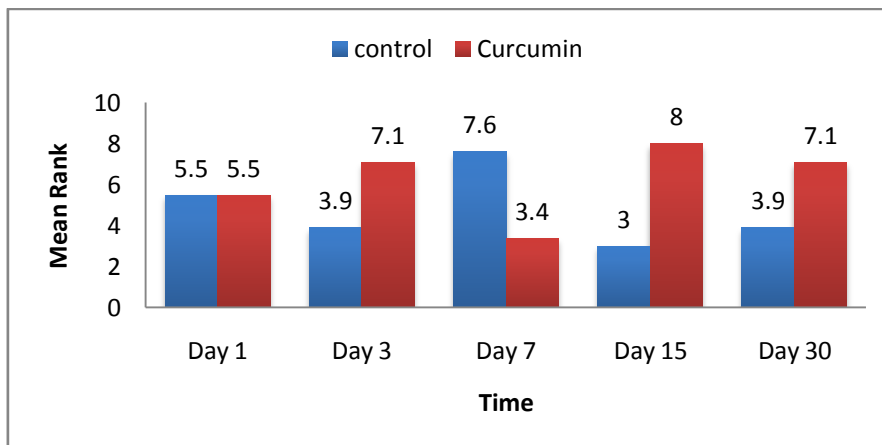


Fig. (7): Mann-Whitney mean ranks for re-epithelialization in control and curcumin treated skin wounds.

Table (4) Mann-Whitney test comparing between inflammation and re-epithelialization in control and curcumin treated mucosal wounds.

Duration	Inflammation (p-value)	Re-epithelialization
Day 1	0.008 (*)	0.169
Day 3	0.008 (*)	0.240
Day 7	0.020 (*)	0.043 (*)
Day 15	0.065	0.228
Day 30	0.307	0.334

Significance (*), P value ≤ 0.05 .

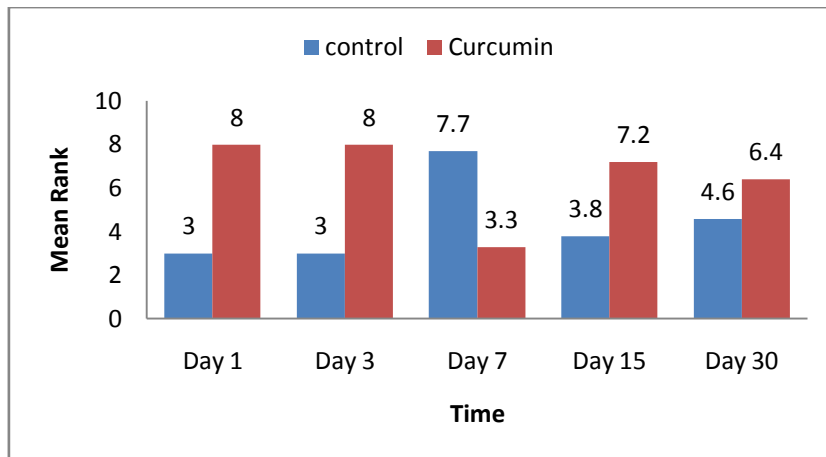


Fig (8): Mann-Whitney mean ranks for inflammation in control and curcumin-treated mucosal wounds.

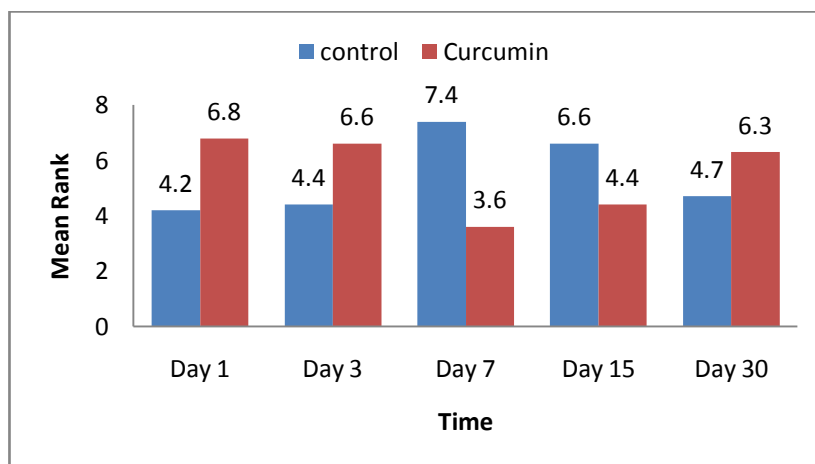


Fig (9): Mann-Whitney mean ranks for re-epithelialization in control and curcumin-treated mucosal wounds.

Serum concentration of IL-6 and TNF- α in control and curcumin treated groups showed fluctuation during various time periods 1,3,7,15 and 30 post-wounding days (Table 5 and 6).

The ANOVA statistical test comparing between serum concentration of IL-6 in control and curcumin treated groups showed significantly lower ($P < 0.05$) concentration in curcumin treated group in the 1 and 15 post-wounding day and significantly higher ($P < 0.05$) concentration in curcumin treated group in the 7 and 30 post-wounding day (Table 5), while ANOVA statistical test comparing between serum concentration of TNF- α in control and curcumin treated groups showed significantly higher ($P < 0.05$) concentration in 15 post-wounding day (Table 6).

Table (5): The mean values of serum concentration of IL-6 of control and curcumin treated groups at various post-wounding days.

Groups	Day 1	Day 3	Day 7	Day 15	Day 30
Control group	50.00 ^(*)	12.50	0.00 ^(*)	12.50 ^(*)	1.50 ^(*)
Curcumin group	23.75	7.00	13.00	3.40	18.60

Significance (*), P value < 0.05.

Table (6): The mean values of serum concentration of TNF- α of control and curcumin treated groups at various post-wounding days.

Groups	Day 1	Day 3	Day 7	Day 15	Day 30
Control group	25.00	20.50	35.00	37.50 ^(*)	37.50
Curcumin group	20.50	16.25	31.60	170.8	32.40

Significance (*), P < 0.05.

DISCUSSION

In the present study, curcumin was found to have an enhancing effect on the healing of both oral and skin wounds by accelerating re-epithelialization, reducing inflammation, stimulating fibroplasia, and enhancing wound remodeling. This finding is in accordance with those of other studies^[22,30,31,32]. Kumari *et al.* (2017)^[30] investigated the wound healing potential of curcumin in the carp, *Labeo rohita* and found that in the curcumin treated group, healing of skin wounds was enhanced in comparison with those in the sham group (fish with skin wounds without curcumin) as indicated by early restoration of morphology of the surface layer of epithelial cells and early granular tissue formation, collagen deposition and tissue remodeling in dermal layer. Zhang *et al.* (2016)^[31] demonstrated that topical or systemic administration of a phenylaminocarbonyl (triketonic rather than diketonic) curcumin substantially improved wound healing in skin of the severely hyperglycemic type 1 diabetic rat. The wound healing potential of curcumin has been attributed to its antioxidant activity^[22,33]. Reactive oxygen species (ROS) are inevitably by-products of aerobic respiration and have essential role in some biochemical and cellular processes including intracellular messaging, differentiation, apoptosis, cell progression, and immunity^[34,35].

ROS are also important in wound healing as they are important for immune system defense against microorganisms. However, the prolonged presence of ROS at high concentrations generates oxidative stress which can cause cell injury^[12,36]. Oxidative stress has a great influence on the wound healing process and in general inhibits tissue remodeling^[37]. ROS such as superoxide(O₂⁻) and hydrogen peroxide (H₂O₂) can be used as quantitative markers for oxidative stress^[34]. Oxidative stress causes oxidative damage, leading to DNA breakage, enzyme inactivation and lipid peroxidation, all of which inhibit optimum wound healing. ROS has been considered the major cause of inflammation during the wound healing process^[32]. Free radicals also damage tissue proteins and for this reason they must be effectively scavenged^[38]. Anti-oxidant enzymes such as superoxide dismutase, catalase and glutathione peroxidase protect the tissue against toxic reactive oxygen species^[35]. Antioxidants with free radical scavenging potential have been found to significantly enhance wound healing when applied topically^[35]. Gopinath *et al.* (2004)^[39] studied the in vitro antioxidant efficiency of curcumin incorporated collagen matrix (CICM) using the lipid peroxidation test, and he found that curcumin exhibited scavenging action against the peroxy radicals. In another study, transdermal application of curcumin on excision wounds in rats induced significant inhibition of H₂O₂-induced damage to keratinocytes and fibroblasts^[40]. Similarly, it has been found in vitro that curcumin protected keratinocytes and fibroblasts against hydrogen peroxide^[14]. Topical application of curcumin on excised wounds on the back of rats caused a significant rise in the antioxidant enzymes catalase, superoxide dismutase and glutathione peroxidase^[12].

Another explanation for the enhancing effect of curcumin is the regulation of various transcription and growth factors, inflammatory cytokines, protein kinases, and several enzymes^[41,42]. Curcumin protects skin by quenching free radicals and reduces inflammation through inhibition of nuclear factors- κ B. It accelerates wound healing, improves collagen deposition and increases fibroblasts and vascular density in healing wounds. It induces transforming growth factor- β and stimulates angiogenesis and accumulation of extracellular matrix which continue through the remodeling phase of wound repair^[43].

REFERENCES

- [1]. Joe, B. and Lokesh, B.R. (1994). Role of capsaicin, curcumin and dietary n-3 fatty acids in lowering the generation of reactive oxygen species in rat peritoneal macrophages. *Biochem. Biophys. Acta*, 1224: 255 – 263
- [2]. Brouet, I. and Oshima, H. (1994). Curcumin an anti-tumor promoter and anti-inflammatory agent inhibits induction of nitric oxide synthase in activated macrophage. *Biochem. Biophys. Res. Commun.* 206: 533 – 540.
- [3]. Chan, M.M.; Huang, H.I.; Fenton, M.R. and Fong, D. (1998). In vivo inhibition of nitric oxide synthase gene expression by curcumin, a cancer preventive natural product with anti-inflammatory properties. *Biochem. Pharmacol.*, 55: 1955 – 1962.
- [4]. Dorai, T.; Cao, Y.C.; Dorai, B.; Buttyan, R. and Katz, A.E. (2001). Therapeutic potential of curcumin in human prostate cancer. III. Curcumin inhibits proliferation induces apoptosis and inhibits angiogenesis of LNCaP.
- [5]. Araujo, C. and Leon, L. (2001). Biological activities of curcumin longa L. *Mem. Inst. Oswaldo Cruz.*, 96: 23 – 28.
- [6]. Bartine, H. and Tanaoui – Elaraki, A. (1997). Growth and toxigenesis of *Aspergillus flavus* isolates on selected species. *J. Environ. Pathol. Toxicol. Oncol.*, 16: 61 – 65.
- [7]. Barthelemy, S.; Vergnes, L.; Moynier, M.; Guyot, D.; Labidalle, S. and Bahraoui, E. (1998). Curcumin and curcumin derivatives inhibit Tat-mediated transactivation type 1 human immunodeficiency virus long terminal repeat. *Rev. Virol.*, 149: 34 – 52.
- [8]. Ficker, C.E.; Smith, M.L.; Susiarti, S.; Loeman, D.J.; Irawati, C. and Arnson, J.T. (2003). Inhibition of human pathogenic fungi by members of Zingiberaceae used by the Kenyah (Indonesian Borneo). *J. Ethnopharmacol.*, 85(2 – 3): 289 – 293.
- [9]. Fernandes, J.P.; Mello – Moura, A.C.; Marques, M.M.; Nicoletti, M.A. (2012). Cytotoxicity evaluation of curcuma zedoaria (Christm) Roscoe fluid extract used in oral hygiene products. *Acta Odontol. Scand.*, 2012 Jan 18. [Epub ahead of print][Links].
- [10]. Papiiez, M.A. (2013). The influence of curcumin and (-) – epicatechin on the genotoxicity and myelosuppression induced by etoposide in bone marrow cells of male rats. *Drug and Chemical Toxicology*, 36(1): 93 – 101 (doi: 10.3109/01480545.2012.726626).
- [11]. Yang, X.; Jiang, H. and Shi, Y. (2017). Upregulation of heme oxygenase-1 expression by curcumin conferring protection from hydrogen peroxide-induced apoptosis in H9c2 cardiomyoblasts. *Cell Biosci.*, 7: 20.

- [12]. Panchatcharam, M.;Miriyaala,S.;Gayathri,V.S. and Suguna, L.(2006). Curcumin improves wound healing by modulating collagen and decreasing reactive - Shishodia,S.; Sethi,G. and Aggarwal,B.B.(2005).Cucumin:getting back to the roots .Ann.N.Y.Acad.Sci. ,1056 : 206 – 217. oxygen species. Moll. Cell Biochem., 290:87-96.
- [13]. Shishodia,S.; Sethi,G. and Aggarwal,B.B.(2005).Cucumin:getting back to the roots .Ann.N.Y.Acad.Sci. ,1056 : 206 – 217.
- [14]. Phan, T.T.; See, P.; Lee,S.T. and Chan, S.Y.(2001). Protective effects of curcumin against oxidative damage on skin cells in vitro:its implication for wound healing .J. Trauma,51(5):927 – 931.
- [15]. Swarnakar,S.; Ganguly,K.; Kundu,P.; Banerjee, A. Maity,P. and Sharma,A.V.(2005). Curcumin regulates expression and activity of matrix metalloproteinases 9 and 2 during prevention and healing of indomethacin – induced gastric ulcer . J.Biol. Chem., 280(10): 9409 – 9415.
- [16]. Mani,H.; Sidhu, G.S.; Kumari, R.; Gaddipati,J.P.;Seth, P. and Maheshwari,R.K.(2002). Curcumin differentially regulates TGF – beta 1 , its receptors and nitric oxide synthase during impaired wound healing. Biofactors, 16:29 – 43.
- [17]. Chattopadhyay,I; Biswas,K.;Bandyopadhyay,U.; Banerjee,A.(2004).Turmeric and curcumin : biological actions and medicinal applications. Current Sci., 87(1): 44 – 53.
- [18]. Bhagavathula, N.; Warner, R. L.; DiSilva, M.; McClintock, S. D.; Barron, A.; Aslam, M. N.; Johnson, K. J. and varani, J. (2009). A combination of curcumin and ginger extract improves abrasion wound healing in corticosteroid-damaged hairless rat skin. Wound Repair and Regeneration, 17(3): 360-375.
- [19]. Jagetia, G.C. and Rajanikant,G.K.(2004). Effect of curcumin on radiation –impaired healing of excisional wounds in mice. J. Wound Care, 13(3):107-109.
- [20]. Kulac, M.; Aktas, C.; Tulubas, F.; Uygur, R.; Kanter, M.; Erbogaa, M.; Ceber, M.; Topcu, B.; and Ozen, O.A.(2013). The effects of topical treatment with curcumin on burn wound healing in rats. J. Mol.Histol.,44(1): 83-90.
- [21]. Chereddy, K.K.; Coco, R.; Memvanga, P.B.; Ucakar, B.; des Rieux, A.; Vandermeulen, G. and Preat, V.(2013). Combined effect of PLGA and curcumin on wound healing activity. Journal of Controlled Release, 171(2): 208-215.
- [22]. Akbik, D.; Ghadiri, M.; Chrzanowski, W. and Rohanzadeh, R.(2014). Curcumin as a wound healing agent. Life Sci., 116(1): 1-7
- [23]. Al – Nema,Z.M. (2000). A substitute preparation for " triamcinolone acetone in orabase" for the treatment of recurrent oral aphthous ulceration. M.Sc. Thesis, College of Pharmacy, University of Mosul, Iraq.
- [24]. Paknejad,M.; Rokn,A.R.; Eslami,B.; Afzalifar,R. and Safiri,A. (2007). Evaluation of three bone substitute materials in the treatment of experimentally induced defects in rabbit calvaria . J.Dentist., 4(4): 171 – 175
- [25]. Kilic,N. (2004). A comparison between medetomidine – ketamine and xylazine – ketamine anesthesia in rabbits. Turk. J. Vet. Anim. Sci., 28: 921 – 926.
- [26]. Camacho – Alonso, F.; Jornet, P.L. and Fenoll, A.B.(2005). Effects of scalpel (with and without tissue adhesive) and cryosurgery on wound healing in rat tongues. Oral Surg. Oral Med. Oral Pathol. Oral Radiol. Endod., 100: 58 – 63.
- [27]. Camacho – Alonso, F. ; Jornet, P.L.; Torres, M.J. and Domingo, A.O.(2008). Analysis of the histopathological artifacts in punch biopsies of the normal oral mucosa. Med. Oral Pathol. Oral Cir. Bucal., 13(10): 636 – 639.
- [28]. Lopez – Jornet, P.; Alosa, F.C. and MezGarei, A.F.(2009). Effects of plasma rich in growth factors on wound healing of the tongue: experimental study in rabbits. Med. Oral Pathol. Oral Cir. Bucal.,14(9): 425 – 428.
- [29]. Albanaa, R.F.(2010). Histopathological effect Epiglu surgical adhesive versus black silk suture on oral incisional primary wound healing: a comparative experimental study. M.Sc. Thesis , University of Mosul, Iraq, pp: 45 – 54.
- [30]. Kumari,U.; Verma,N.; Nigam,A.K.; Mittal,S. and Mittal,A.K.(2017). Wound healing potential of curcumin in the Carp,Labeo rohita. Aquaculture Research, 48(5): 2411-2427.
- [31]. Zhang, Y.; McClain,S.; Lee,H-M; Elburki,M.S.; Yu,H.; Gu,Y. et al.(2016). A novel chemically modified curcumin "Normalizes" wound healing in rats with experimentally induced type 1 diabetic: Initial studies. J. Diabetes Res., 2016: 5782904.
- [32]. Mohanty, C.; Das, M. and Sahoo, S.K. (2012). Sustained wound healing activity of curcumin loaded oleic acid based polymeric bandage in a rat model. Mol. Pharmaceutics, 2012. 9 (10). pp 2801 – 2811, DOI: 10. 1021/ mp 300075.u.
- [33]. Elsayed,A.S.(2016). The curcumin as an antioxidant natural herb, with emphasize on its effects against some diseases.Int.J.Applied Biol.Pharmaceutical Technology, 7(1):26 – 40.
- [34]. Inlay,J.A.(2003). Pathway of oxidative damage. Annu.Res.Microbiology, 57:395 – 418.
- [35]. Mates,J.M.; Perez-Gomez,C. and DeCastro,I.N.(1999). Antioxidant enzymes and human diseases. Biochem. 32:595 – 603.
- [36]. Roy,S.; Klanna,S.; Kuhn,D.E.; Rink,C.; Williams,W.T.; Zweier,J.L. and Sen,C.K.(2006). Transcriptome analysis of the ischemia-reperfused remodeling myocardium:temporal changes in inflammation and extracellular matrix . Physiol.Genomics, 25(3):364 – 74.
- [37]. Thangapazham,R.L.; Sharad,S. and Naheshwari,R.K.(2013).Skin regenerative potentials of curcumin. BioFactors, 39(1):141 – 149.
- [38]. Kapoor,S. and Priyadarsini,K.I.(2001). Protection of radiation – induced protein damage by curcumin. Biophys.Chem. 92: 119 – 126.
- [39]. Gopinath, D.; Ahmed, M.R.; Gomathi, K.; Chitra, K.; Sehgal, P.K. and Jayakumar, R.(2004). Dermal wound healing processes with curcumin incorporated collagen films. Biomaterials, 25:1911-1917.
- [40]. Gadekar, R.; Saurabh, M.K.; Thakur, aG.S.; and Saurabh, A. (2012). Study of formulation, characterization and wound healing potential of transdermal patches of curcumin. Asian Journal of Pharmaceutical and Clinical Research, 5(Suppl.4): 225-230.
- [41]. Mehrabani, D.; Farjam, M.; Geramizadeh, B.; Tanideh, N.; Amini, M.; and Panjehshahin, M.R.(2015). The healing effect of curcumin on burn wounds in rats. World J. Plast.Surg.,4 (1):29-35.
- [42]. Shishodia,S.; Singh,T. and Chaturvedi,M.M.(2007). Modulation of transcription factors by curcumin. Adv.Exp.Med.Biol., 595:127 – 148.
- [43]. Thangapazham, R.L.; Sharma,A. and Maheshwari, R.K. (2007). Beneficial role of curcumin in skin diseases. Adv. Exp. Med. Biol., 595:343.