

Review of literature with case series

“Lymphangioma of Cheek”- A Clinical Rarity

Dr. Shivendra Choudhary¹, Dr. Abhay Taranath Kamath², Dr. Deepika Pai³,
Dr Daya Shankar⁴, Dr Amit Dahiya⁵, Dr Minakshi Rana⁶

¹MDS, Associate Professor, Department of Dentistry, Patna Medical College, Patna, Bihar, India 800004.

²MDS, Professor and Head, Department of Oral and Maxillofacial Surgery, Manipal College of Dental Sciences, Manipal, Karnataka, 576104

³MDS, Associate Professor, Department of Pedodontics and Preventive dentistry, Manipal College of Dental Sciences, Manipal, Karnataka, 576104

⁴MDS, Senior Resident, Department of Dentistry, Patna Medical College, Patna, Bihar, India 800004.

⁵MDS, Senior Resident, Department of Orthodontics, Post Graduate Institute of Dental Sciences, Pt. BD Sharma

University of Health Sciences, Rohtak – 124001

⁶MDS, Consultant Periodontist, Rohtak -124001

ABSTRACT

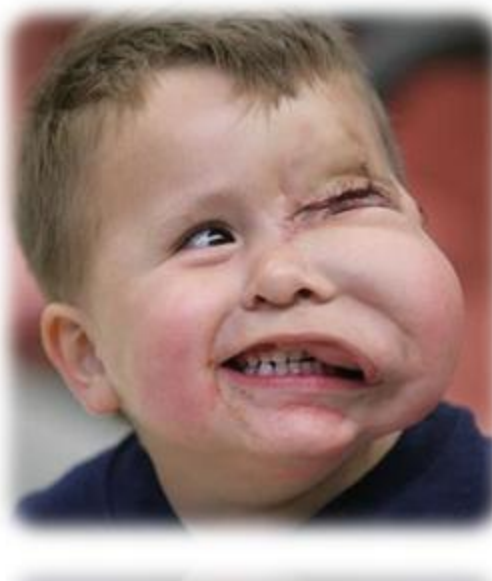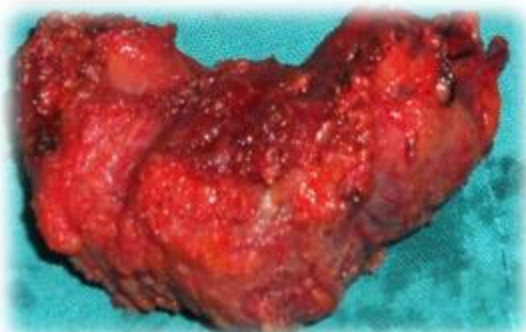
Lymphatic malformations are developmental defects of the lymphatic system, frequently present at birth and are most commonly found in head and neck region. May also involve the axilla, chest wall, abdominal wall, thighs. Many treatment modalities have been proposed but surgical excision of the lesion remains the mainstay. Most lymphangiomas are benign lesions that result only in a soft, slow-growing, "doughy" mass. Since they have no chance of becoming malignant, lymphangiomas are usually treated for cosmetic reasons only. Rarely, impingement upon critical organs may result in complications, such as respiratory distress when a lymphangioma compresses the airway. Treatment includes aspiration, surgical excision, laser and radiofrequency ablation, and sclerotherapy. This paper presents a case report of a 16 years old female with complaint of swelling and pain on left side of the face. She gave a history of being operated for facial swelling when she was two years old. The swelling was present since birth and gradually increased to the present size. Ultrasound left cheek and neck with Doppler study and MRI plain and contrast of upper neck suggested a venous vascular malformation and lymphohemangioma as a working diagnosis. Patient was posted for surgical excision of lesion under General anesthesia. The final histopathological report confirmed the diagnosis as Cavernous Lymphangioma

Keywords- lymphatic malformation, congenital, venous vascular malformation, lymphohemangioma, cavernous lymphangioma, surgical excision

INTRODUCTION

Lymphatic malformations are developmental defects of the lymphatic system, frequently present at birth and are most commonly found in head and neck region but very rare on the cheek. It may also involve the axilla, chest wall, abdominal wall, thighs. Many treatment modalities have been proposed but surgical excision of the lesion remains the mainstay.

Most lymphangiomas are benign lesions that result only in a soft, slow-growing, "doughy" mass. Since they have no chance of becoming malignant, lymphangiomas are usually treated for cosmetic reasons only. Rarely, impingement upon critical organs may result in complications, such as respiratory distress when a lymphangioma compresses the airway. Treatment includes aspiration, surgical excision, laser and radiofrequency ablation, and sclerotherapy.



CASE HISTORY

A 16 years old female was referred from pediatric surgery unit to Maxillofacial Surgery Out Patient Department with complaint of swelling and pain on left side of the face. She gave a history of being operated for facial swelling when she was two years old. The swelling was present since birth and gradually increased to the present size. At the age of 9 months she developed fever and simultaneous pain over the swelling region and was treated symptomatically for it. At the age of 2 years with a differential diagnosis of lymphatic cyst the patient was posted for Subtotal Excision of the mass. The Histopathological report of the excised mass showed fibromuscular tissue with dilated lymphatic channels lined by flattened endothelial cell wall showing nodular collections of lymphocytes, capillaries and adipose tissue; Features were consistent with Lymphangioma.

EXTRAORAL EXAMINATION:

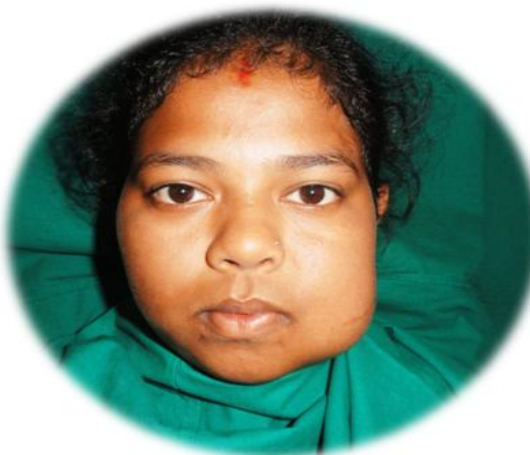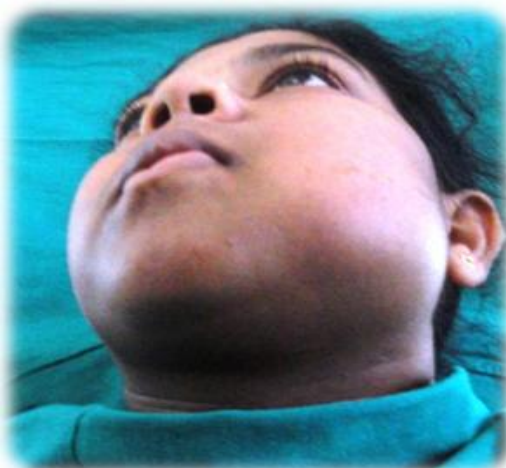Gross facial asymmetry.

Swelling:

Vertical: inferior border of mandible with ill defined superior extensions.

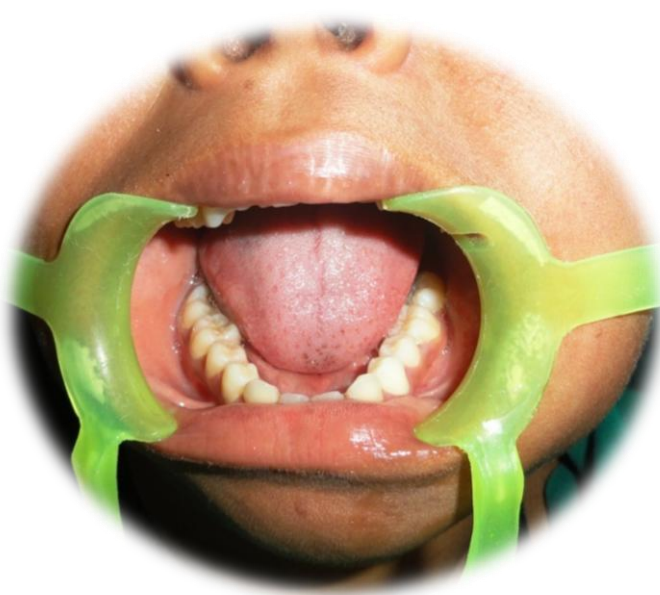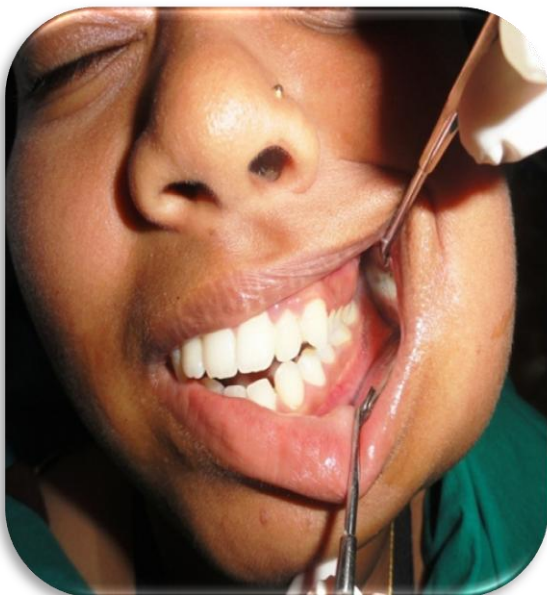Antero-posterior: corner of mouth till just anterior to tragus region

Tender on palpation but No local rise in temperature.



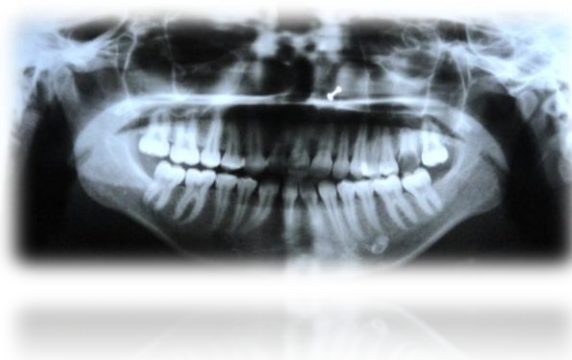
INTRAORAL EXAMINATION:

An Obliteration of the buccal vestibule on left side with Grade II mobile of first lower molar was seen. However, no signs of pus discharge or sinus or fistula present.



PRE OPERATIVE WORKUP:

- 1) OPG and Puffed cheek
- 2) USG left cheek and USG of neck with Doppler study
- 3) MRI plain and contrast of upper neck
- 4) All routine blood and biochemical investigations
- 5) Nutritional support
- 6) Cardiac evaluation



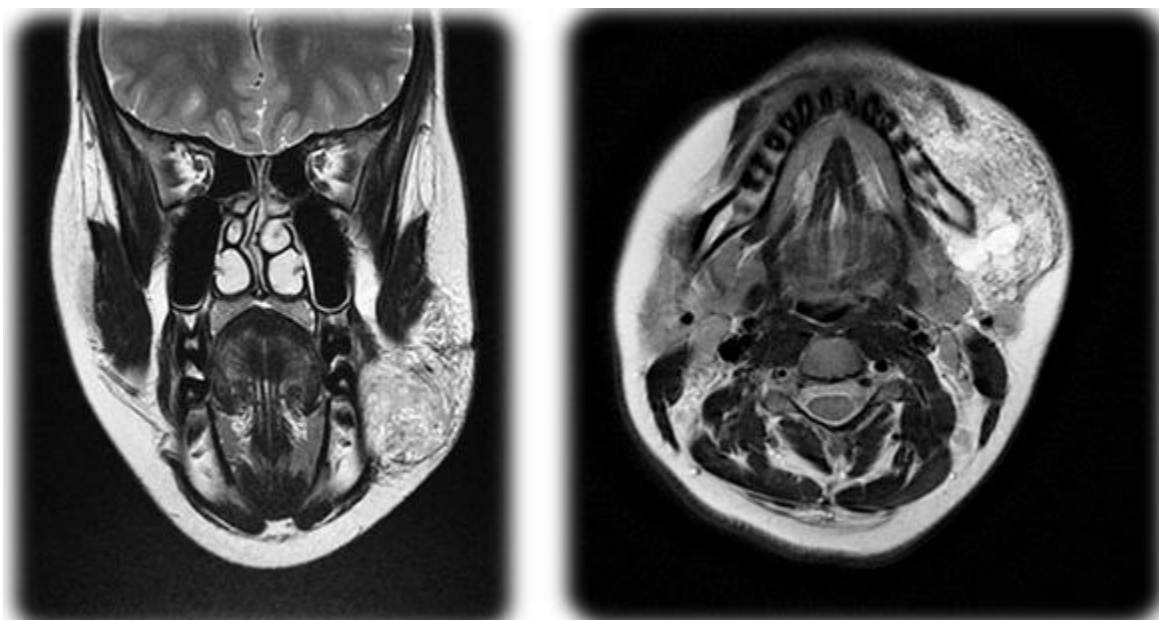
The **ultrasound sound of left cheek** showed an ill defined lesion with multiple small anechoic spaces in the subcutaneous and intramuscular plane of the left maxillary region involving the masseter and buccinators muscles. No evidence of colour flow within these cystic spaces.

Superiorly the lesion extended up to the level of zygomatic arch and inferiorly to the submandibular space abutting the submandibular gland. However the submandibular gland was normal and there was no evidence of infrahyoid extension. Anteriorly the extension was up to the angle of mouth on the left side and posteriorly behind the ramus of mandible. However, there was no evidence of extension into posterior triangle. Left parotid gland was normal in echogenicity,

however, small intra parotid lymphnode with maintained fatty hilum measuring 7x4 mm seen. Impression- possibility of Lymphangiona to be considered.

The **ultrasound sound of left neck** gave an impression of ill defined heterogenous lesion involving the soft tissues of left cheek with multiple anechoic compressible sinusoidal spaces which show colour uptake with venous spectral pattern. Suggestive of venous vascular malformation and an advice to get an MRI cheek for further evaluation.

MRI Cheek both plain and contrast gave an impression of well defined heterogenous intensely enhancing mixed solid cystic lesion in the left buccal and masticator space with possibility of lymphohemangioma to be considered.



INTRAOPERATIVE STEPS

Fig 1: incision(pre auricular extending to submandibular region)

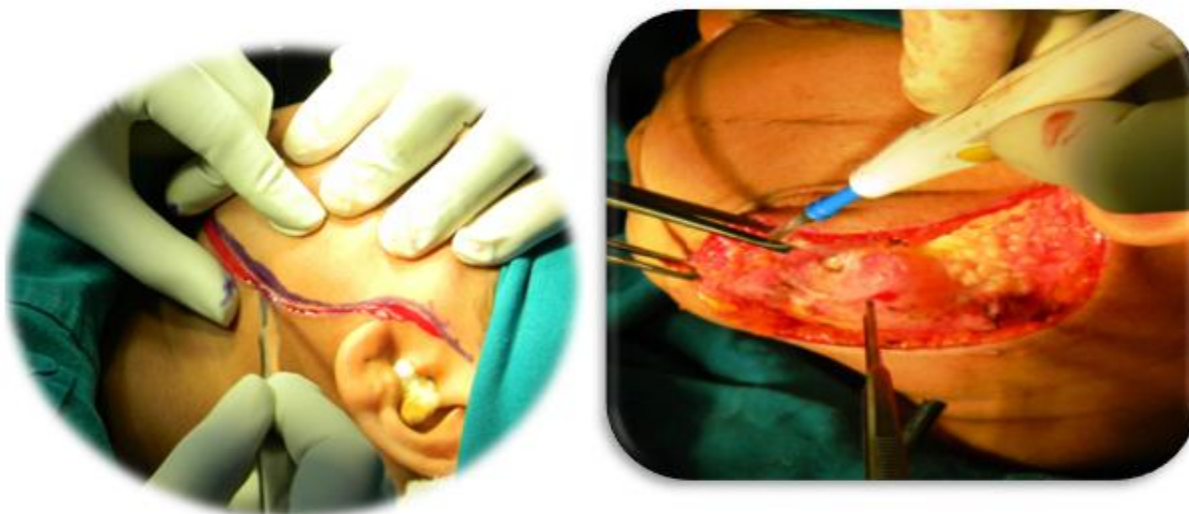
Fig 2-7:Exposure of the Lesion and release of peripheral attachments of mass

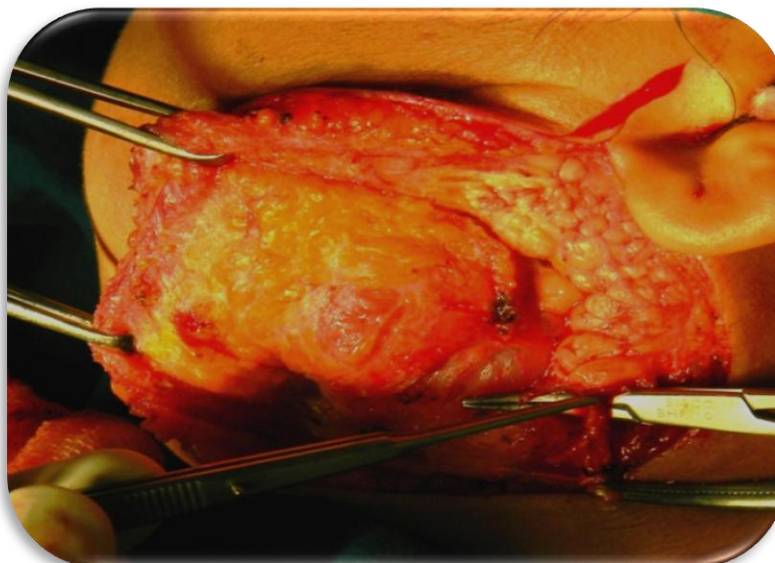
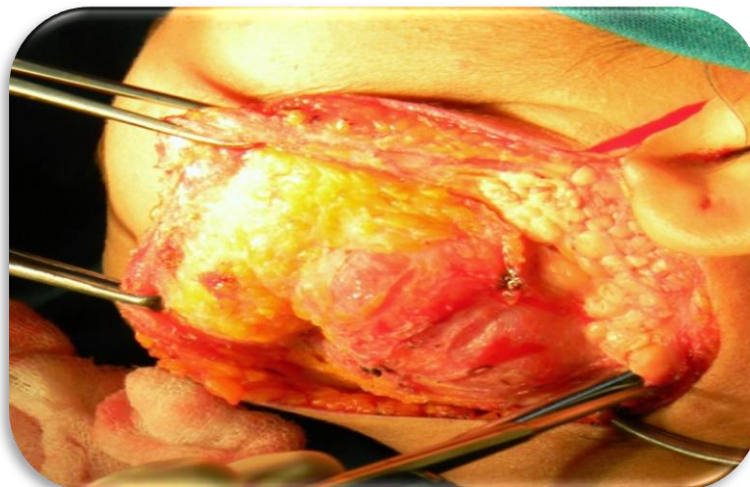
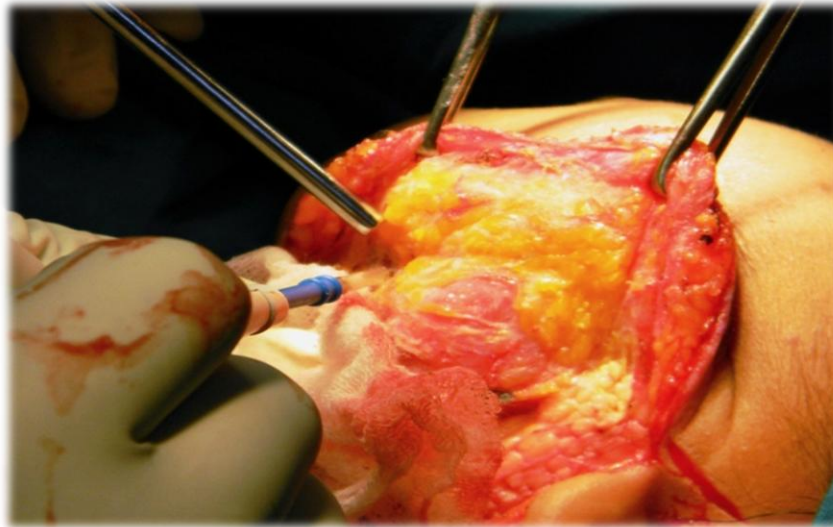
Fig 8- Resected tumor/mass

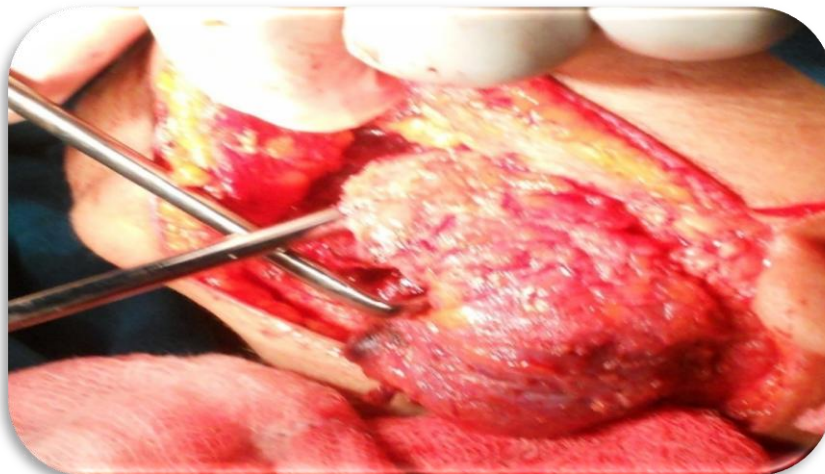
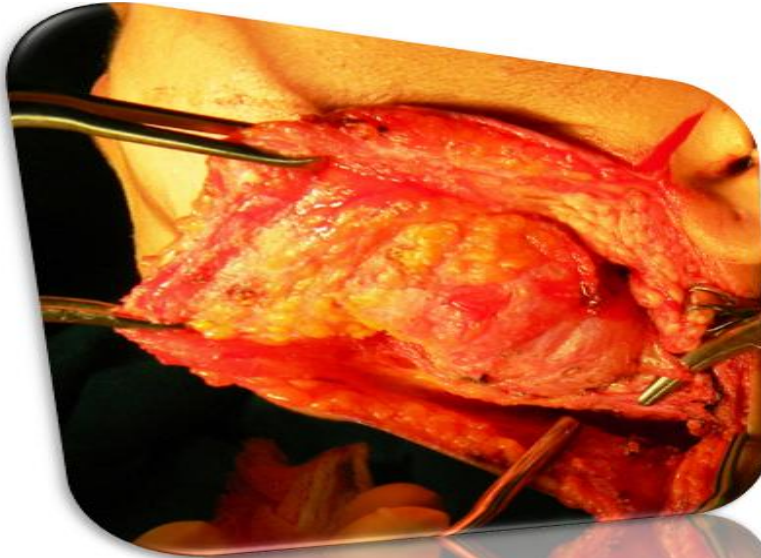
Fig 9- site after removal of tumour showing intact mandible

Fig 10- Drain Placed and secured

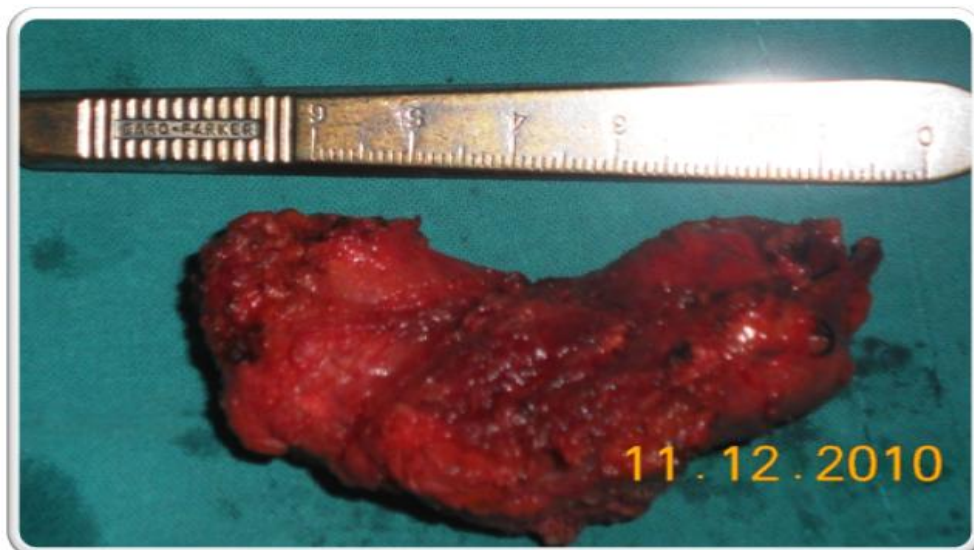Fig 11-Suturing complete



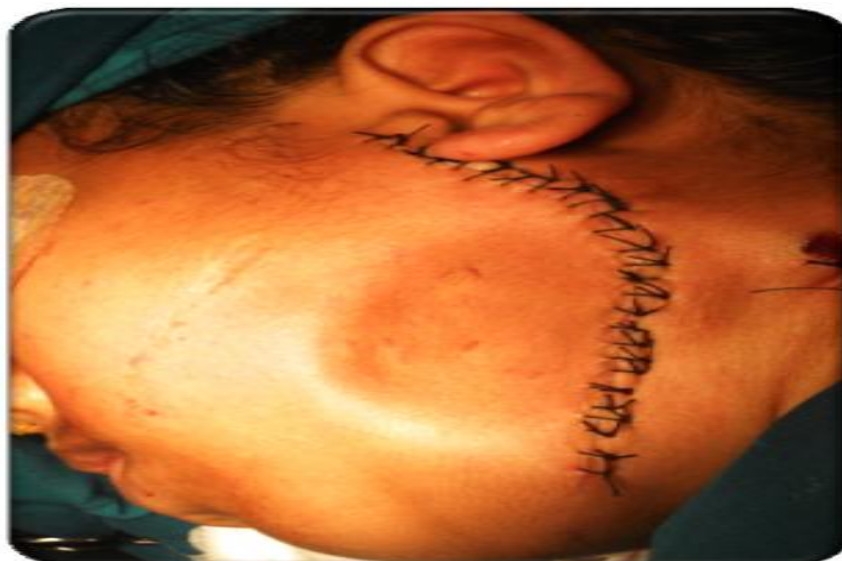
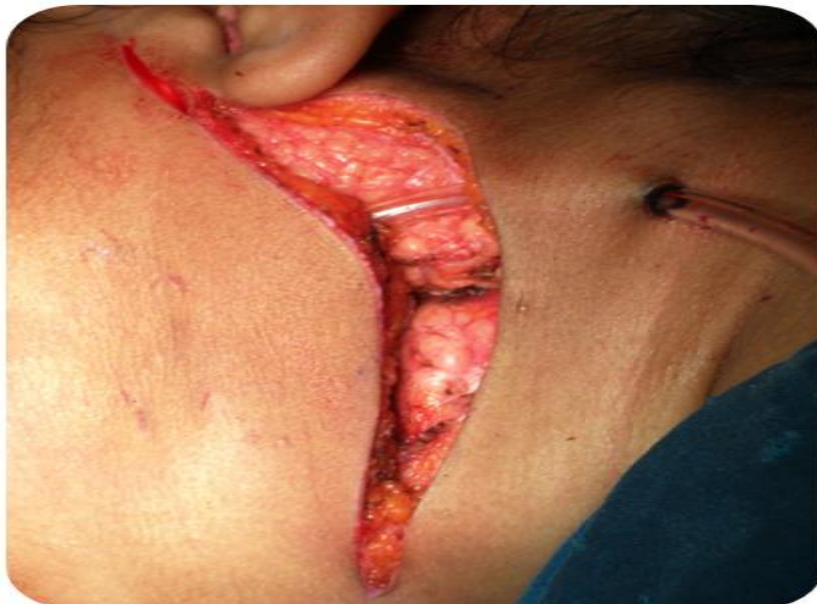
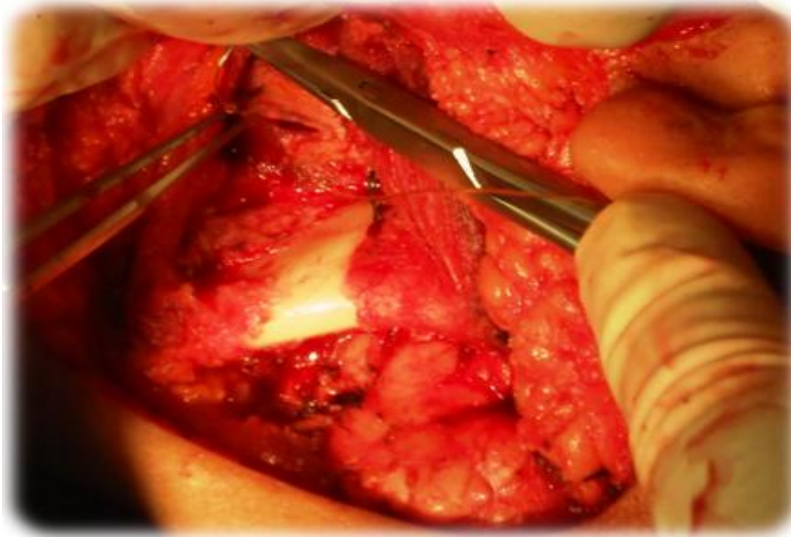

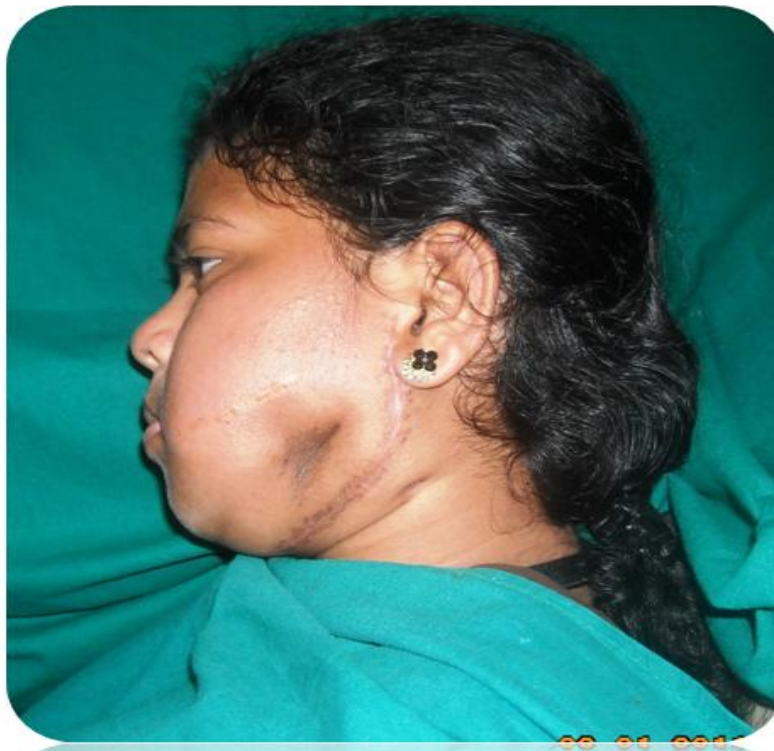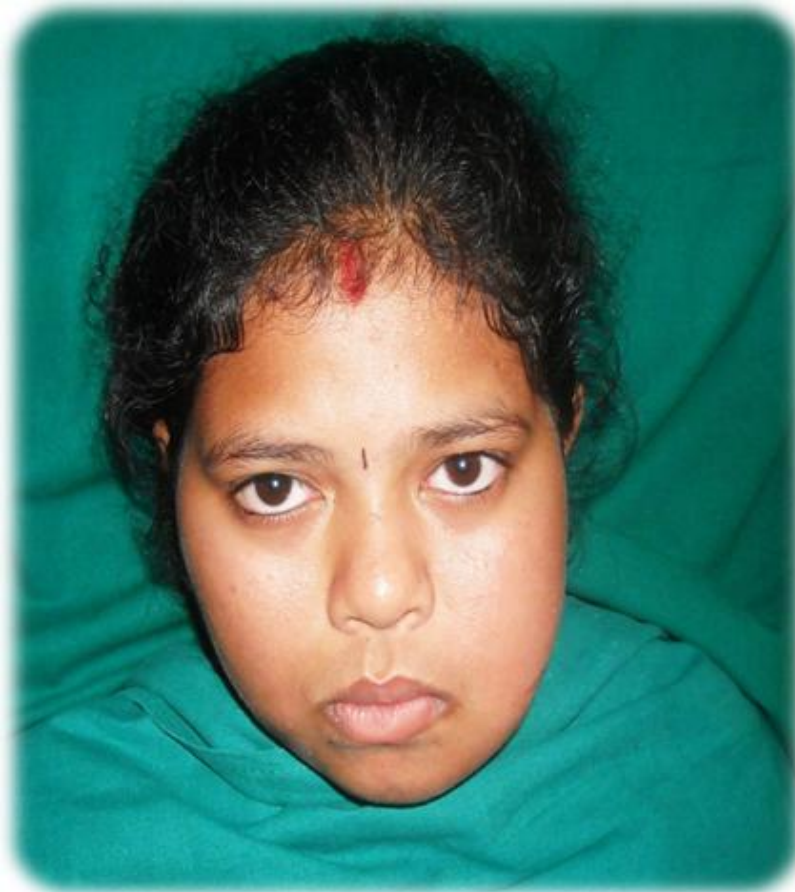RESECTED LESION



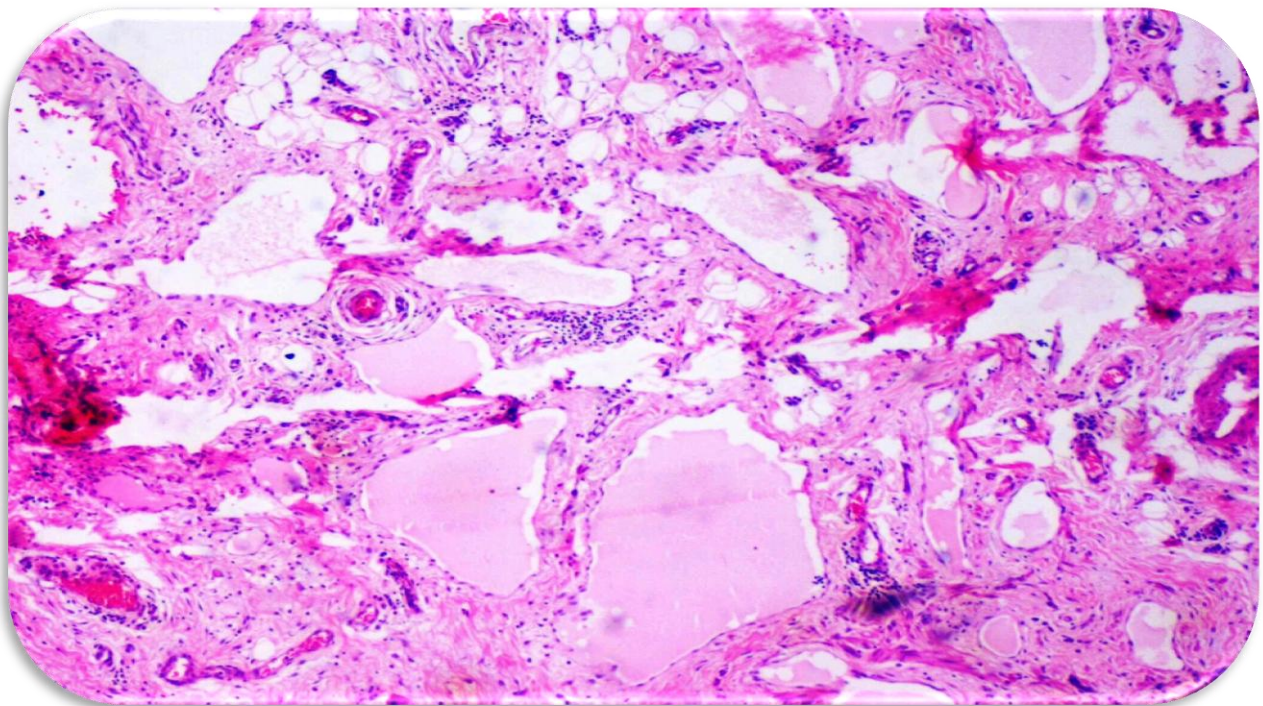
Weight-32 grams. Measuring 6x4 and 5x2.5 cms



POST OPERATIVE STATUS



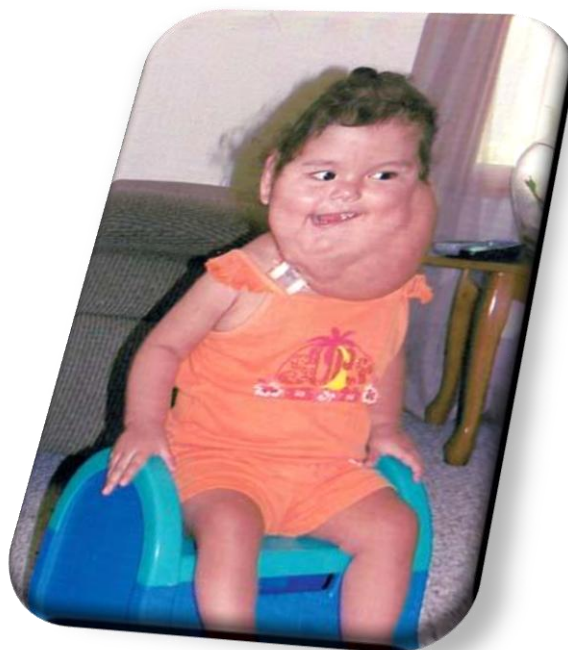HISTOPATHOLOGICAL PICTURE



Cut section was compressible, spongy with multiple tiny cystic areas, largest measuring 1cm, filled with serous fluids. Microsections showed numerous thin walled irregularly dilated interconnected lymphatic channels lined by flattened endothelium, with few attenuated layers of smooth muscle, with many containing proteinaceous fluid, surrounded by fibrocollagenous stroma containing few tiny congested capillaries, focal lymphocytic infiltrate, with lymphoid follicle formation, extending in between skeletal muscle and adipose tissue. Diagnosis- Cavernous lymphangioma

DISCUSSION

Lymphatic malformations occur as a wide spectrum from localized masses to areas of diffuse infiltration .It is Usually noted at birth but can be seen at any age . Skin and soft tissues are most commonly affected .



CLASSIFICATION[1]

- 1) 4 SUBTYPES (Microscopic characteristics)
 - a) Capillary
 - b) Cavernous
 - c) Cystic hygromas
 - d) Hemangiolymphangioma.
- 2) According to the size of the cyst
 - a) Microcystic < 2 cm³ in volume
 - b) Macrocystic > 2 cm³ in volume
 - c) Mixed : Both types
- 3) According to location and extent of disease :
 - a) Stage I: Unilateral infrahyoid
 - b) Stage II: Unilateral suprahyoid
 - c) Stage III: Unilateral suprahyoid and infrahyoid
 - d) Stage IV: Bilateral suprahyoid
 - e) Stage V : Bilateral suprahyoid and infrahyoid

Signs and symptoms

There are three distinct types of lymphangioma, each with their own symptoms. They are distinguished by the depth and the size of abnormal lymph vessels, but all involve a malformation of the lymphic system. Lymphangioma circumscription can be found on the skin's surface, and the other two types of lymphangiomas occur deeper under the skin.

- Lymphangioma circumscription, a microcystic lymphatic malformation, resembles clusters of small blisters ranging in color from pink to dark red.[2] They are benign and do not require medical treatment, although some patients may choose to have them surgically removed for cosmetic reasons.
 - Cavernous lymphangiomas are generally present at birth, but may appear later in the child's life.[3] These bulging masses occur deep under the skin, typically on the neck, tongue and lips,[4] and vary widely in size, ranging from as small as a centimeter in diameter to several centimeters wide. In some cases, they may affect an entire extremity such as a hand or foot. Although they are usually painless, the patient may feel mild pain when pressure is exerted on the area. They come in the colors white, pink, red, blue, purple, and black; and the pain lessens the lighter the color of the bump.
 - Cystic hygroma(5) shares many commonalities with cavernous lymphangiomas, and some doctors consider them to be too similar to merit separate categories. However, cystic lymphangiomas usually have a softer consistency than cavernous lymphangiomas, and this term is typically the one that is applied to lymphangiomas that develop in fetuses. They usually appear on the neck (75%), arm pit or groin areas. They often look like swollen bulges underneath the skin.
- Causes

The direct cause of lymphangioma is a blockage of the lymphatic system as a fetus develops, although symptoms may not become visible until after the baby is born. The cause remains unknown. Why the embryonic lymph sacs remain disconnected from the rest of the lymphatic system is also not known.[6]

Cystic lymphangioma that emerges during the first two trimesters of pregnancy is associated with genetic disorders such as Noonan syndrome and trisomies 13, 18, and 21. Chromosomal aneuploidy such as Turner syndrome or Down syndrome[7] were found in 40% of patients with cystic hygroma.[8]

Diagnosis

Cases of lymphangioma are diagnosed by histopathologic inspection.[9] In prenatal cases, cystic lymphangioma is diagnosed using an ultrasound; when confirmed ,amniocentesis may be recommended to check for associated genetic disorders.

Treatment

Treatment for cystic hygroma involves the removal of the abnormal tissue; however complete removal may be impossible without removing other normal areas. Surgical removal of the tumor is the typical treatment provided, with the understanding that additional removal procedures will most likely be required as the lymphangioma grows. Most patients need at least two procedures done for the removal process to be achieved. Recurrence is possible but unlikely for those lesions able to be removed completely via excisional surgery.[10] Radiotherapy and chemical cauteries are not as effective with the lymphangioma than they are with the hemangioma.[11] Draining lymphangiomas of fluid provides only temporary relief, so they are removed surgically. Cystic Hygroma can be treated with OK432 (Picibanil).(16)

The least invasive and most effective form of treatment is now performed by interventional radiologists. A sclerosing agent, such as 1% or 3% sodium tetradecyl sulfate, doxycycline, or ethanol, may be directly injected into a lymphocele. "All sclerosing agents are thought to work by ablating the endothelial cells of the disrupted lymphatics feeding into the lymphocele." [12]

Lymphangioma circumscription can be healed when treated with a flashlamp pulsed dye laser, although this can cause port-wine stains and other vascular lesions.[13]

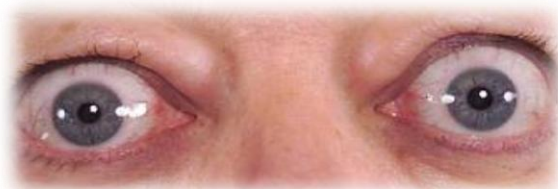Prognosis

The prognosis for lymphangioma circumscription and cavernous lymphangioma is generally excellent. This condition is associated with minor bleeding, recurrent cellulitis, and lymph fluid leakage. Two cases of lymphangiosarcoma arising from lymphangioma circumscription have been reported; however, in both of the patients, the preexisting lesion was exposed to extensive radiation therapy.

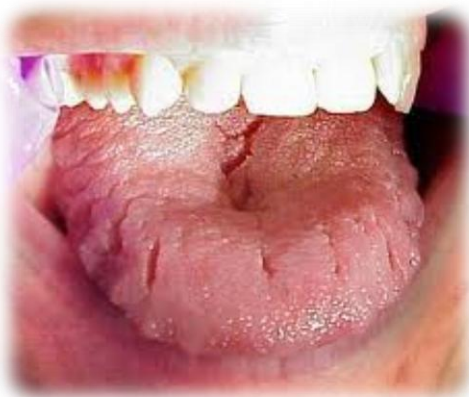In cystic hygroma, large cysts can cause dysphagia, respiratory problems, and serious infection if they involve the neck. Patients with cystic hygroma should receive cytogenetic analysis to determine if they have chromosomal abnormalities, and parents should receive genetic counseling because this condition can recur in subsequent pregnancies.[6]

COMPLICATIONS(14)

- Periorbital lymphatic malformation: Proptosis



Facial lymphatic malformation: Macrocheilia Macroglossia



G.I.T : loss of chyle and protein losing enteropathy

GORHAM SYNDROME : soft tissues and skeletal LMs lead to progressive osteolysis and disappearing bone disease .
Pathologic fracture and vertebral instability can occur with this condition .

Complications after surgical removal of cystic hygroma include damage to the structures in the neck, infection, and return of the cystic hygroma.[10]

TREATMENT(14)

Surgical resection provides the only method for potential cure. Focal and macrocystic lesions are amenable to ablation by both sclerotherapy and resection. More diffuse and complex LMs sclerotherapy procedures are staged and can lead to improvement . The site of the lesion is the most important determinant for a successful curative surgical procedure. Lesions involving multiple anatomic sites recurred more frequently after surgery than did lesions confined to single site.

SOME OTHER CAVEATS OF SURGICAL MANAGEMENT OF LYMPHANGIOMA (14)

- Cervicofacial lymphangiomas will often require staged orthognathic procedure to improve bite and speech problems.
- Tracheostomy may be needed in cases of oropharyngeal and airway obstruction .

- Lesions of the cervical and axillary regions often involve the brachial plexus . Nerve stimulation can be a useful adjunct to prevent injury in such cases .

CAUSES FOR RECURRENCE (15)

Recurrence varies between 18 to 56 % and is documented

1)Due to postoperative dilation of persistent anomalous channels resulting from scarring and obstruction or localized lymphatic proliferation .

2) It may also be influenced by imbalance of angiogenic mediators.

USE OF OK- 432 AS A SCLEROSING AGENT FOR THE MANAGEMENT OF LYMPHANGIOMA(16)

- OK-432 (picibanil) is a biological preparation consisting of lyophilized powder containing cells of *Streptococcus pyogenes* treated with benzylpenicillin potassium .
- Currently used as a sclerosing agent in the management of lymphangioma .

CONCLUSION

- Lymphatic malformations are developmental defects of lymphatic system.
- Frequently present at birth , and most commonly seen in head and neck region.
- Surgical excision of the lesion is the main treatment modality for lymphatic malformation in head and neck .