

A Rare Case of Recurring Trichilemmal Cyst on the Eyelid in a Male with no family History

Dr. Kavya Bansal

(Resident), Shyam Shah Medical College, Rewa

INTRODUCTION

1. Trichilemmal cyst is also known as pilar cyst and arises from the outer sheath of hair follicle.[1]
2. It is round, firm, smooth nodule with no punctum visible.
3. Familial, inherited in autosomal dominant pattern.[2]
4. Eyelid is an uncommon site and very few cases have been reported and mostly in females.
5. It can undergo malignant changes.[3]

CASE REPORT

- ❖ A twenty nine year old male presented to the eye OPD with a painless, progressive round swelling over the upper lid in the middle one third of left eye.
- ❖ He had undergone excision at other centre twice before diagnosing it as a chalazion however the swelling recurred.
- ❖ No known case of any systemic disease.

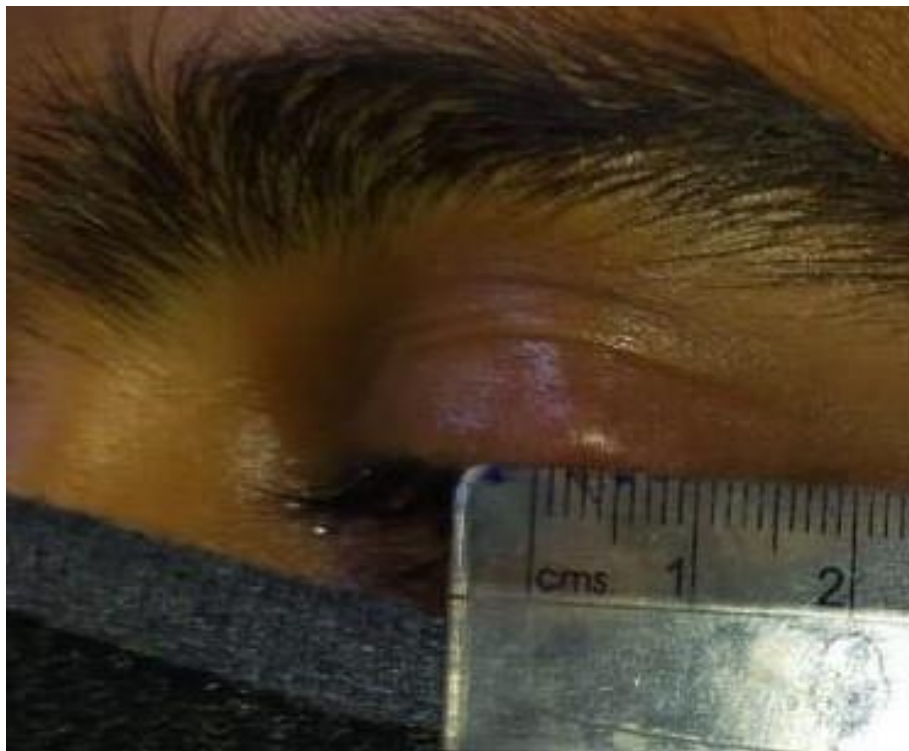
FAMILY HISTORY:

- ❖ No one in the family had similar history. GENERAL EXAMINATION: Moderately built, conscious oriented. SYSTEMIC EXAMINATION: WNL.

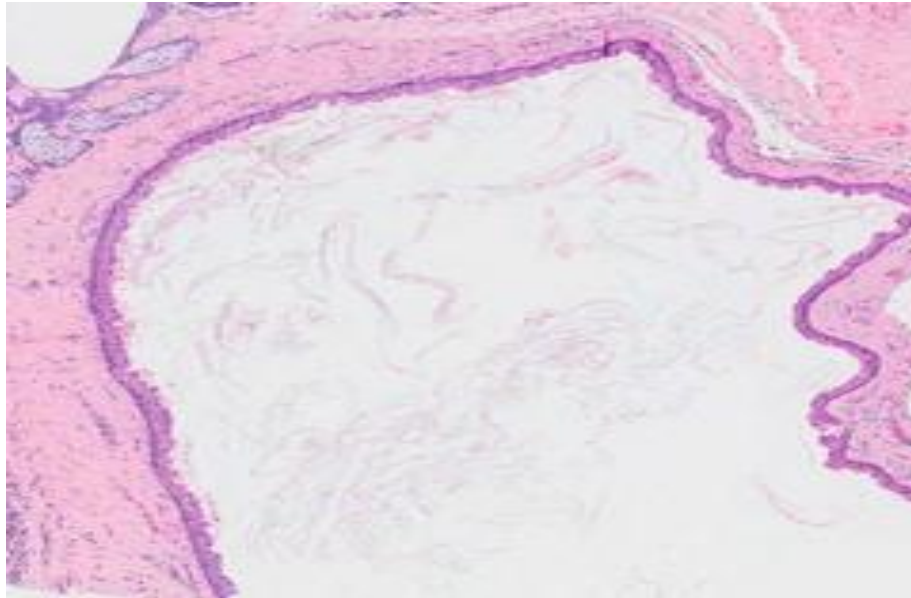
OCULAR EXAMINATION

	RIGHT EYE	LEFT EYE
VISION	UNCORRECTED : 6/9 BCVA: 6/6	UNCORRECTED: 6/9 BCVA: 6/6
LID	NORMAL	Circular swelling of size 0.5*0.5cm, firm, non-tender, present in middle one third of upper lid.

CONJUNCTIVA	Normal	Normal
CORNEA	WNL, clear	WNL, cornea
ANT. CHAMBER	Depth and content Normal	Depth and content normal
IRIS, PUPIL	WNL	WNL
LENS	TRANSPARENT	TRANSPARENT
OCULAR MOVEMENTS	WNL	WNL



Circular firm swelling of size 0.5*0.5cm



Histology – trichilemmal cyst

MANAGEMENT

Blood investigation: Within Normal Limits

- ❖ Swelling excised and sent for biopsy.
- ❖ Biopsy revealed keratinised stratified squamous epithelium of eye lid with a cyst filled with homogenous, amorphous, keratinous material suggestive of trichilemmal cyst with no malignant changes.
- ❖ Patient developed it again one month after excision.

DISCUSSION

- ❖ Reported to be found in other tissues like upper lip, conjunctiva, index finger, curuncle. [4,5,]
- ❖ Eyelid is an extremely rare site.
- ❖ Trichilemmal cysts can turn malignant.[3]
- ❖ Can be often confused with chalazion, should be kept as a differential diagnosis. [6]
- ❖ As evident can recur after excision. Newer modalities in surgical management to be pondered upon.

CONCLUSION

Occurrence of trichilemmal cyst on the eyelid in a male is an uncommon finding and can be confused as chalazion.

It can have multiple recurrences at the lid (4 times in this patient).

Despite recurrences Excision or Incision & Drainage remain best known modality of treatment.

We hereby conclude newer options can be explored to prevent the recurrence.

REFERENCES

- [1]. N.Adachi and T. Yamashita, “Trichilemmal cyst of the scalp: MR Imaging”, American Journal Of Roentgenology, vol. 154, no 2, pp.423-424, 1990.
- [2]. G.Ikizoglu T.I.Kaya, U.Tursen, K.Baz, “The use of free dissector for the removal of trichilemmal cysts”, International Journal of Dermatology, vol.42, no.5, pp.405-407, 2003.



- [3]. S.J. Lee, K. H. Choi, J.H. Han et al., “Malignant proliferating trichilemmal tumor of the lower eyelid,” *Ophthalmic Plastic & Reconstructive Surgery*, vol. 21, no. 5, pp. 349-352, 2005.
- [4]. L.M. Perrez, J. W. Bruce, V. A. Murrah et al., “Trichilemmal cyst of the upper lip,” *Oral Surgery, Oral Medicine, Oral Pathology, Oral Radiology & Endodontics*, vol. 84, no 1, pp. 58-60, 1997.
- [5]. D. Elder, R. Elenitas, and B. Ragsdale, “Tumors of the epidermal appendages,” in *Lever’s Histopathology of the Skin*, D. Elder, R. Elenitas, and C. Jaworsky, Eds., pp. 749-799, Lippincott Williams & Wilkins, Philadelphia, Pa, USA, 1997.
- [6]. Lippincott Williams & Wilkins, Philadelphia, Pa, USA, 1997
- [7]. Meena M, Mittal R, Saha D. “Trichilemmal cyst of the eyelid: Masquerading as recurrent chalazion. Case Rep Ophthalmol Med. 2012; 2012: 261414.