International Journal of Enhanced Research in Medicines & Dental Care (IJERMDC),
ISSN: 2349-1590, Vol. 4 Issue 11, November-2017, Impact Factor: 1.338

Recent Advances to Monitor Early Revascularization for Assessment of Postsurgical Healing: A case report

Monika Khangwal[1], Ravinder Solanki[2], Jogender Kumar[3], Monika Khokhar[4]

[1]Consultant Endodontist, Shri Ganesh Dental & Maxillo-Facial Clinic, Rohtak (Haryana)
[2]Associate Professor, Department of Oral and Maxillofacial Surgery, Post Graduate Institute of Dental Sciences, Rohtak (Haryana)
[3]Consultant Oral Surgeon, Shri Ganesh Dental & Maxillo-Facial Clinic, Rohtak (Haryana)
[4]Consultant Endodontist, Shri Ganesh Dental & Maxillo-Facial Clinic, Rohtak (Haryana)

ABSTRACT

Endodontic infections with periapical lesions are usually diagnosed conventional radiological findings. Ultrasound with color doppler has potentials to examine physiological conditions and investigate suspected pathology and mask the limitations of conventional radiography. It can differentiate between cystic and non cystic lesion as well as monitor the healing of periapical lesions Hence this present case report have focused on effectiveness of ultrasound, color doppler imaging and radiography to monitor periapical healing post endodontic surgery.

INTRODUCTION

Conventional radiography is physician's first diagnostic aid as it is employed commonly in routine. Endodontic infections with periapical lesions are usually diagnosed and treated with conventional radiological findings. However due to 2-D view it limits to reach conclusive diagnosis on the ground of dimensions and content of the lesions. [1,2] Recent advances in digital imaging have revolutionized every sphere of science and technology. Ultrasound with color doppler has potentials to examine physiological conditions and investigate suspected pathology. [3, 4] The use of ultrasound in the differential diagnosis of periapical lesions was introduced by Cotti et al. in 2002 and 2003.[5,6] It can differentiate between cystic and noncystic lesion as well as monitor the healing of periapical lesions.[7,8,9] It provide three-dimensional imaging in detection of tissue harmonies and presence, direction, and velocity of blood flow within the examined tissue.[5.6,7,8] Hence this present case report have focused on effectiveness of ultrasound, color doppler imaging and radiography to monitor periapical healing post endodontic surgery.

CASE REPORT

A healthy 26 year old patient reported with a chief complaint of extra-oral intermittent pus discharge in maxillary anterior region in the Department of Conservative Dentistry and Endodontics. The patient experienced no pain, and there was no medical history and was not on any medication. Patient had history of trauma 17-16 year's back and had undergone incomplete endodontic therapy. An electronic pulp tester (Digitest D626D; Parkell Electronics, New York, NY), cold test (Endo-Ice – The Hygienic Corporation, Ohio, USA) and a heat test (application of hot gutta-percha) yielded no response in this region. Left side maxillary incisors were sensitive to percussion. A periapical radiograph showed a periapical radiolucent area associated with 11 teeth (shown in figure 1). Endodontic surgery was planned in this region after complete blood investigation as well as digital imaging and conventional radiography. Prior to apicocectomy IOPA i.e. intra oral periapical radiograph, ultrasound and color imaging of the concerned area was done (as shown in fig 1,2). After achieving complete local anesthesia (2% lidocaine with 1:80000 adrenalin) rct, root end resection and removal of the resorptive defect, curretage of granulation tissue followed by rootend filling with MTA (angeulus) was performed. Post operative antibiotic and anti-inflammatory was prescribed. One week later (post operative), IOPA , ultrasound and color imaging was performed and assessed to analyze- (as shown in fig 3,4)

a) Size, shape and dimensions on the anteroposterior, superoinferior and mesiodistal plane.
b) Quantative and qualitative analysis of vascularity in the affected area
The similar parameters were assessed postoperatively after 6 months follow up ((as shown in fig 5,6).

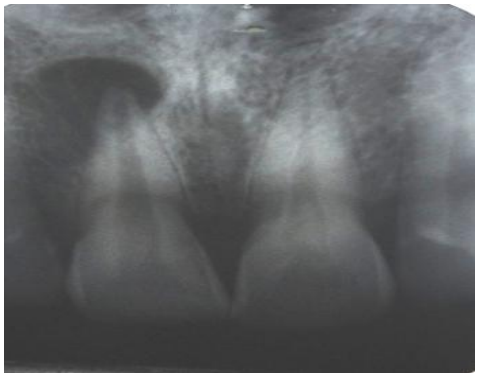

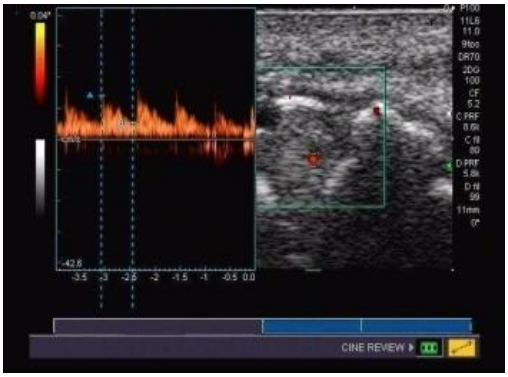

Figure 1: periapical radiograph showed a periapical radiolucent area associated with 11 tooth
Figure 2: periapical radiolucency showing in ultrasound with color Doppler wrt 11tooth

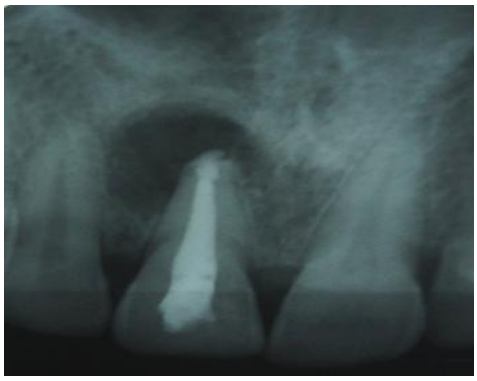

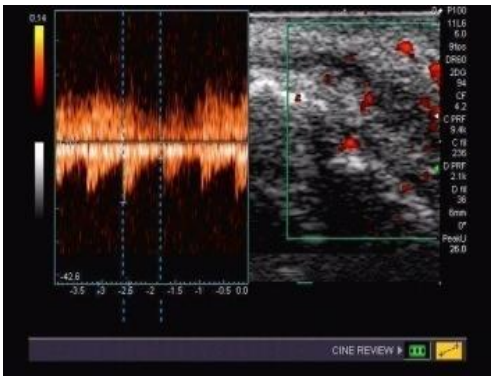

Figure 3: 1 week post operative periapical radiograph
Figure 4: 1 week post operative ultrasound with color Doppler

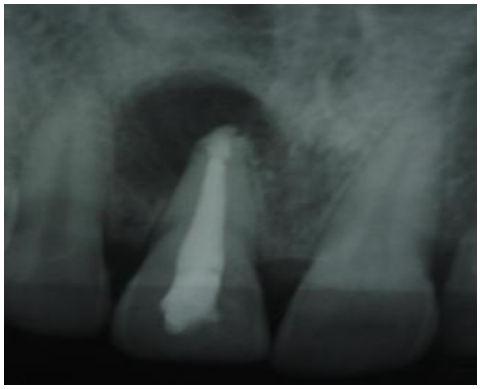

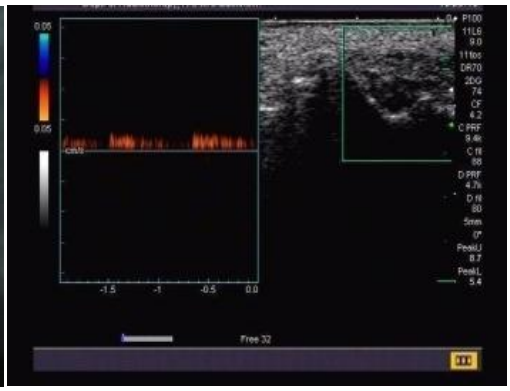

Figure 5: 6 months post operative periapical radiograph
Figure 6: 6 months post operative ultrasound with color Doppler

DISCUSSION

Detection periapical granuloma or cyst is difficult due to the diffuse and infiltrative nature of the inflammatory process in bone. Conventional radiography due to insensitivity and blind techniques was unable to measure and monitor small incremental periradicular changes.[1,2,3] Cotti et al defined cystic lesion as a hypoechoic well-contoured cavity filled with fluids with no evidence of internal vascularity on power doppler imaging, and granuloma as a hyperechoic or mixed hyper-

and hypoechoic areas with a rich vascular supply.[9] Gundappa et al reported that ultrasound had high diagnostic accuracy in the differentiation of periapical granulomas and radicular.[10] Different buccal cortical bone thickness and limitation of total reflection of ultrasound waves by thicker, intact bone questioned diagnostic capability of ultrasound and color doppler examination in detecting and diagnosing periapical lesions in different regions of maxilla and mandible.[11] Internal vascularization at intial stages can be well assessed with color Doppler imaging. ultrasound with color doppler observation in this case showed widespread granulation tissue with widespread areas containing polymorphonuclear neutrophills, lymphocytes, monocytes along with newly formed blood vessels showing neovascularization. ultrasound may not establish the definitive diagnosis but it can facilitate the differential diagnosis between cystic and solid granulomatous lesions. Solid lesion showed hypoechoic image and anechoic image is indicative of a cystic lesion. Hence treatment including biopsy in solid lesion and complete enucleation in cystic lesion could be performed. Biopsy should be done in all inconclusive ultrasound examination before treatment. Color doppler monitor initial revascularization and blood flux level in the area hence aid Postsurgical assessment of healing.

CONCLUSION

It was concluded that ultrasound as a complimentary method for the diagnosis of periapical lesions of endodontic origin and color Doppler for assessment of postoperative healing via neo-revascularization. However, this technique may have a limited role in the region with thick overlying cortical bone.

REFERENCES

[1]. Bender IB, Seltzer S. Roentgen graphic and direct observation of experimental lesions in bone I. J Am Dent Assoc. 1961;62:152–60.
[2]. van der Stelt PF. Experimentally produced bone lesions. Oral Surg Oral Med Oral Pathol. 1985;59:306–12. [PubMed]
[3]. Goldman M, Pearson AH, Darzenta N. Endodontic success-who's reading the radiograph? Oral Surg Oral Med Oral Pathol. 1972;33:432–7. [PubMed]
[4]. Patel S, Dawood A, Whaites E, Pitt Ford T. New dimensions in endodontic imaging: Part 1. Conventional and alternative radiographic systems. Int Endod J. 2009;42:447–62. [PubMed]
[5]. Cotti E, Campisi G, Garau V, Puddu G. A new technique for the study of periapical bone lesions: Ultrasound real time imaging. Int Endod J. 2002;35:148–52. [PubMed]
[6]. Cotti E, Campisi G, Ambu R, Dettori C. Ultrasound real-time imaging in the differential diagnosis of periapical lesions. Int Endod J. 2003;36:556–63. [PubMed]
[7]. Cotti E, Campisi G. Advanced radiographic techniques for the detection of lesions in bone. Endod Topics. 2004;7:52–72.
[8]. Siostrzonek AR, Kozowski R, Morawiec T. Ultrasonography in detection of periapical lesions - Preliminary report. Dent Med Probl. 2007;44:445–8.
[9]. N. Rajendran, B. Sundaresan Efficacy of ultrasound and color power Doppler as a monitoring tool in the healing of endodontic periapical lesionsJ Endod, 33 (2007), pp. 181-186
[10]. M. Gundappa, S.Y. Ng, E.J. WhaitesComparison of ultrasound, digital and conventional radiography in differentiating periapical lesions Dentomaxillofac Radiol, 35 (2006), pp. 326-333
[11]. V. Aggarwal, A. Logani, N. ShahThe evaluation of computed tomography scans and ultrasounds in the differential diagnosis of periapical lesions J Endod, 34 (2008), pp. 1312-1315