

Surgical Management of double fracture of Subcondyle and Parasymphysis Fracture of mandible: A Case Report

Ravinder Solanki¹, Mahesh Goel², Neha Saini³, Jishnu Mohan⁴

^{1,2} Professor, Department of Oral & Maxillofacial Surgery, PGIDS, Rohtak, Haryana

^{3,4} Post Graduate Student, Department of Oral & Maxillofacial Surgery, PGIDS, Rohtak, Haryana

ABSTRACT

Mandibular condylar fractures are among the most common facial fractures and sometimes the difficult to manage. Opinions about the management of mandibular condylar fractures varies among surgeons to surgeons. With the implementation of new technology, an increased understanding of fracture management, and better functional and morphological outcomes reported in the literature, open reduction and internal fixation is becoming many surgeons' preferred choice for the treatment of condylar fractures. Because surgical treatment of such fractures is complex, certain factors must be considered to achieve satisfactory outcomes. In the past, closed reduction with concomitant active physical therapy conducted after a period of intermaxillary fixation during the recovery period had been mainly used, but in recent years, open treatment of condylar fractures with rigid internal fixation has become more common. However, the rigid fixation techniques of treating condyle fractures remain one of the controversial issues in maxillofacial trauma. Several techniques and plate types such as miniplates, minidynamic compression plates, delta plates, and two miniplates have been evaluated biomechanically in various experimental and clinical studies. The present case report is to evaluate the clinical use of titanium 4 hole with gap single miniplate in open treatment and internal fixation of subcondylar fracture.

INTRODUCTION

Subcondyle and parasymphysis fractures of mandible are common types of mandibular fractures, often resulting from high-impact trauma. These fractures pose challenges due to their proximity to vital anatomical structures, such as the temporomandibular joint (TMJ) and inferior alveolar nerve, and their potential impact on occlusion and facial aesthetics. Management of these fractures requires careful assessment and planning. Here, we present a case of combined subcondyl and parasymphysis fracture management, detailing the treatment approach and outcomes.

CASE REPORT

A 34-year-old male patient presented with history of a motor vehicle accident while hitting his face on road towards left side with complaint of pain and difficulty in biting and chewing. On clinical examination patient had diffuse swelling over chin region which was firm and tender on palpation. Temporomandibular joint movements are non palpable over right side along with tenderness in the right preauricular region. There is positive history of oral and right ear bleed. On intraoral examination there is reduced mouth opening with deviation of lower jaw towards right side while mouth opening. Clinically segmental mobility present between mandibular left lateral incisor and mandibular left canine. Occlusion was satisfactory. Thus, the patient was advised orthopantomogram (Fig.1) which reveals right subcondylar fracture and left parasymphysis fracture of mandible. Based on the positive history open treatment and internal fixation was planned for both condyl and parasymphysis. General anesthesia was administered through nasotracheal intubation. The parasymphysis was approached through intraoral vestibular incision from canine to canine. The mucosa and submucosa and periosteum were incised and reflected to expose the fracture fragments. Reduction was done along with fixation using two 4hole with gap 2mm miniplates (Fig.2) as per Champy's criteria. Subcondyl was exposed by retromandibular incision i.e. Hinds approach (Fig.3). Facial nerve in this field was identified and protected. Displaced condylar segment (Fig.4) was retrieved. Anatomical reduction of the fractured fragment was done and held in place till the completion of the miniplate fixation (Fig.5). Internal fixation was done with a 2mm 4 hole with gap single miniplate. Hemostasis was achieved and layered closure of the surgical wound was done at both sites. A post-operative OPG was taken to confirm the position of the condyle and stability of fixation (Fig.6). Postoperative mouth opening

was adequate and satisfactory occlusion was achieved, and thus no intermaxillary fixation was required. Patient was followed up for 6 months and no complications, such as facial nerve palsy, plate bending, plate fracture, screw loosening was encountered.

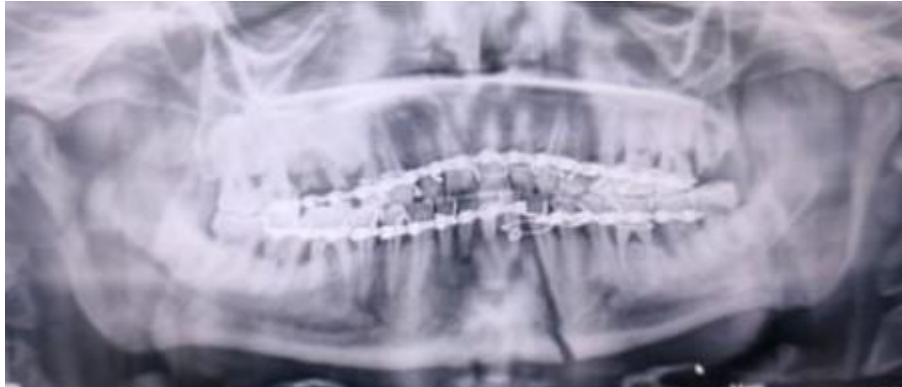


Fig.1 showing orthopantomogram revealing left parasymphysis fracture and right subcondyl fracture

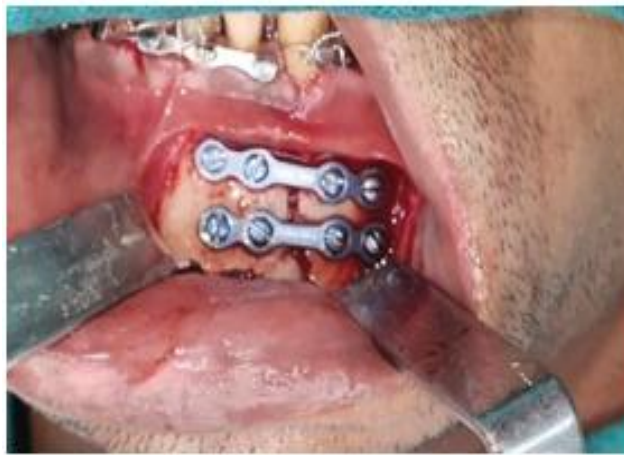

Fig.2 showing fixation using 2 four hole with gap miniplates

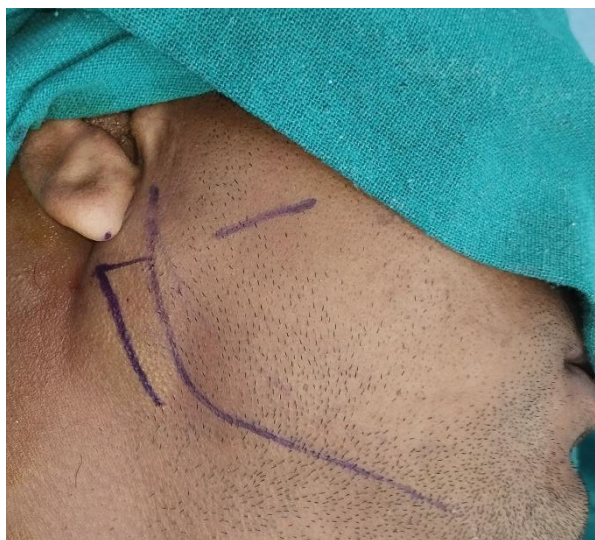

Fig.3 showing marked hind's incision

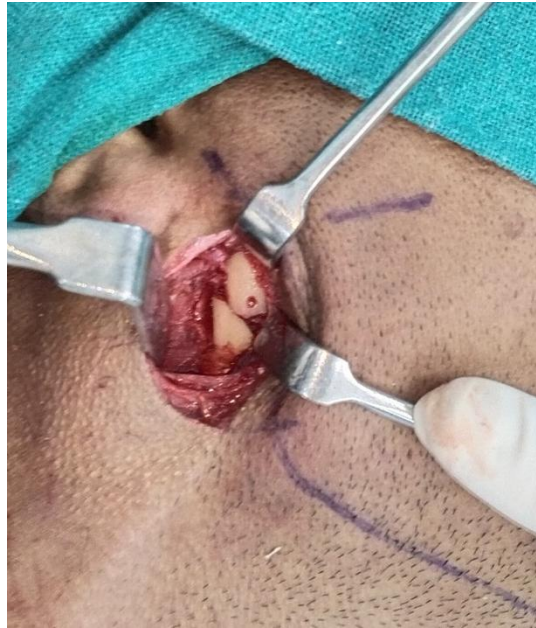

Fig.4 showing overlapping proximal and distal fragments

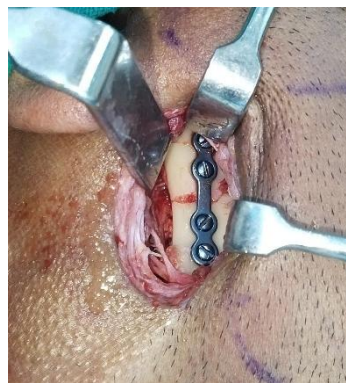

Fig.5 showing fixation after anatomic reduction

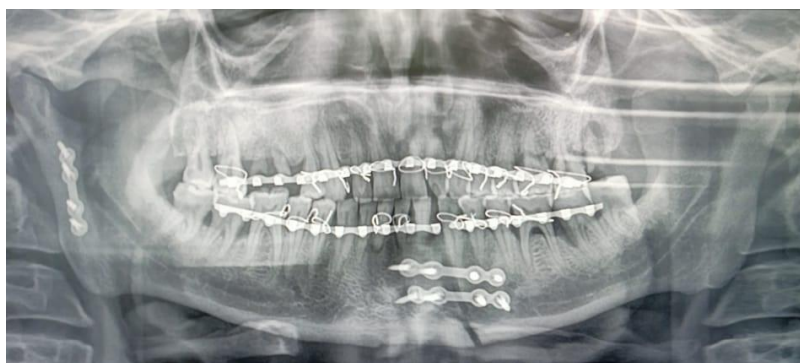


Fig.6 showing postoperative orthopantomogram

DISCUSSION

Condylar fracture in adults can be treated either by closed or open treatment^{1,2}. The type of treatment mainly be chosen on a case-to-case basis and the personal experience of each surgeon. Mainstay of treatment of condylar fracture can be 1) a period of maxillomandibular fixation (MMF) followed by functional therapy; 2) functional therapy without a period of MMF; and 3) open reduction with or without internal fixation^{3,4}. Various factors must be taken into consideration before the choice of treatment is made for the condylar fractures in adult patients, such as: location and type of the fracture lines; unilateral or bilateral type of fractures; total or partial loss of teeth; influence of the affected

TMJ on mandibular movements; degree and direction of dislocation of the condyles; difficulty of surgical access; risk of facial nerve injury; risk of hypertrophic and/or cheloid scar; patient's general health status; presence of other maxillofacial fractures; possibility of performing physical therapy; neuromuscular adaptations⁵.

The absolute indications for open treatment of condylar fractures are patient preference (when no absolute or relative contraindications co-exist), when manipulation and closed treatment cannot re-establish the pretraumatic occlusion; When rigid internal fixation is being used to address another facial fracture affecting the occlusion; When stability of the occlusion is limited (e.g., less than 3 teeth per quadrant, gross periodontal disease, skeletal abnormality); Displacement into the middle cranial fossa; Lateral extracapsular deviation; Open fracture with potential for fibrosis; Invasion by foreign body⁶. In our patient we had normal occlusion but there was deviation of jaw towards right side on mouth opening along with palpable step in left mandibular lateral incisor and left mandibular canine. Thus, we decided to do ORIF for the condylar fracture in this patient. Different methods of fixation have been used for condylar fracture treatment.

These include fixation systems like single 4-hole mini adaptation plate, double fixation with the same plates, single 4-hole mini dynamic compression plate (DCP), Eckelt lag screw system, Wurzburg lag screw plate system and double 4-hole biodegradable miniplates made of poly L-lactide (PLLA). Apart from these fixation systems, various modified single plate systems such as delta plate, trapezoidal plate and A-shaped plates have also been studied. Due to the permanent mediolateral bending⁷ of the condyle during function, a certain stiffness of the plate, a stronger plate, or two plates are recommended. In our patient, the two miniplate technique could not be used because of lack of space for its placement. Since the accessibility to the modified 3D miniplates is limited in the market, we proceeded with the use of conventional 2mm 4 hole with gap single titanium miniplate for the fixation of the condylar fracture.

The plate adaptation and fixation was simple, easy and fast. Post operative complication such as screw loosening, miniplate fracture or bending was not encountered. Patient was able to get full range of mandibular movement and mouth opening during the immediate post operative period. We were also able to avoid intermaxillary fixation (IMF) during the post operative period. In addition, long-term complications such as pain, arthritis, malocclusion, deviation of the mandible on opening and closing movements, temporomandibular joint (TMJ) dysfunction, facial asymmetry, and ankylosis that might be associated in patients with condylar injuries treated in a closed manner may potentially be avoided¹.

CONCLUSION

Treatment of mandibular condylar represent many controversies in the literature. There is a wide array of designs for the fixation system that can be used for ORIF of condylar fractures. Use of 2mm 4hole with gap single miniplate seems to be a simple, effective and reliable alternative for subcondylar fracture management although this has to be further substantiated by a long term clinical and biomechanical studies.

REFERENCES

- [1]. Iwona A. Niedzielska, Anna M. Tomczyk-Wziątek, Bartłomiej P. Borowski. Fractures of the mandibular condylar processes — literature review. *Cent. Eur. J. Med.* 2013 Apr;8(2):244-249.
- [2]. Essam Ahmed, Edward Ellis III. Surgical Treatment of Adult Mandibular Condylar Fractures Provides Better Outcomes Than Closed Treatment: A Systematic Review and Meta-Analysis. *J Oral Maxillofac Surg* 2015;73:482-493.
- [3]. Valiati R, Ibrahim D, Abreu ME, Heitz C, de Oliveira RB, Pagnoncelli RM, Silva DN. The treatment of condylar fractures: to open or not to open? A critical review of this controversy. *Int J Med Sci.* 2008;5(6):313-8.
- [4]. Talwar RM, Ellis III E, Throckmorton GS. Adaptations of the masticatory system after bilateral fractures of the mandibular condylar process. *J Oral Maxillofac Surg* 1998; 56: 430-9.
- [5]. Ellis III E, Throckmorton GS. Treatment of mandibular condylar process fractures: biological considerations. *J Oral Maxillofac Surg* 2005; 63: 115-34.
- [6]. Villarreal PM, Monje F, Junquera LM, Mateo J, Morillo AJ, Gonzalez C. Mandibular condyle fractures: determinants of treatment and outcome. *J Oral Maxillofac Surg* 2004; 62: 155-163.
- [7]. Salvatore P, Alessia S, Stefano P, Pasquale P, Luigi C. Two load sharing plates fixation in mandibular condylar fractures: Biomechanical basis. *J CranioMaxilloFac Surg* 2010; 38, 385-390.